Degenerative disease of the hip and knee, THA and TKA

Dr. Antoniadis

UNIL | Université de Lausanne

Terminology

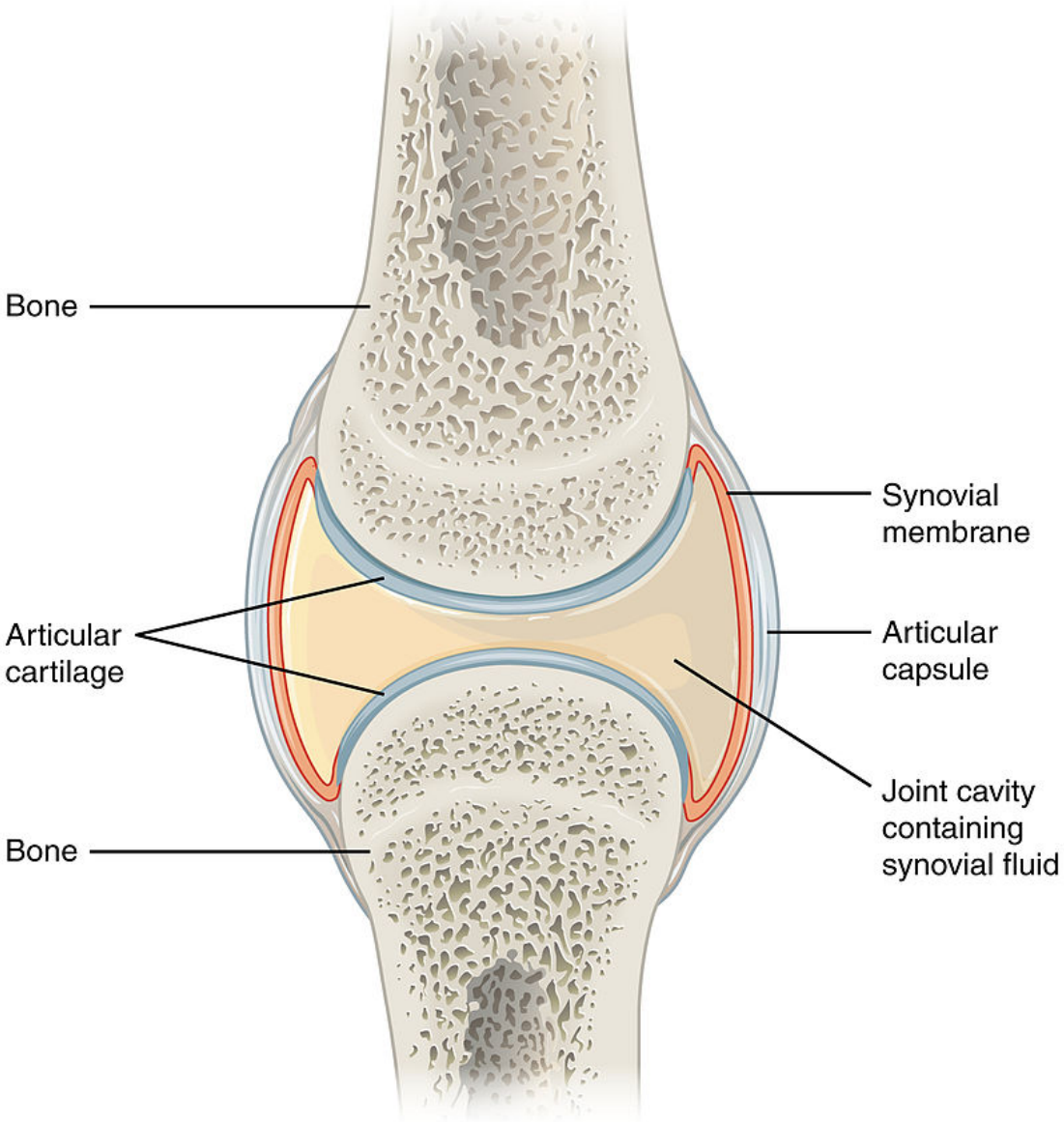

The hip

The hip joint

- Deep joint
- Force and stability
- Weight bearing articulation

The hip joint:

- Proximal femur

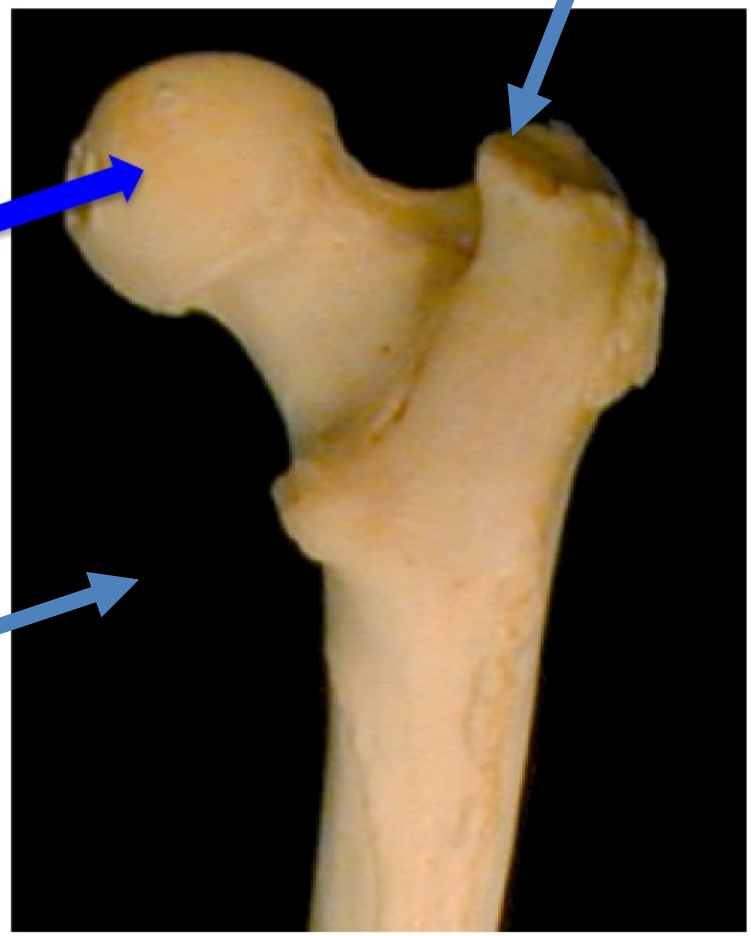

The hip joint:

Acetabulum (etymology)

From acēt(um) (“vinegar”) + -bulum (“a vessel for”)

The hip joint:

Acetabular cavity

labrum

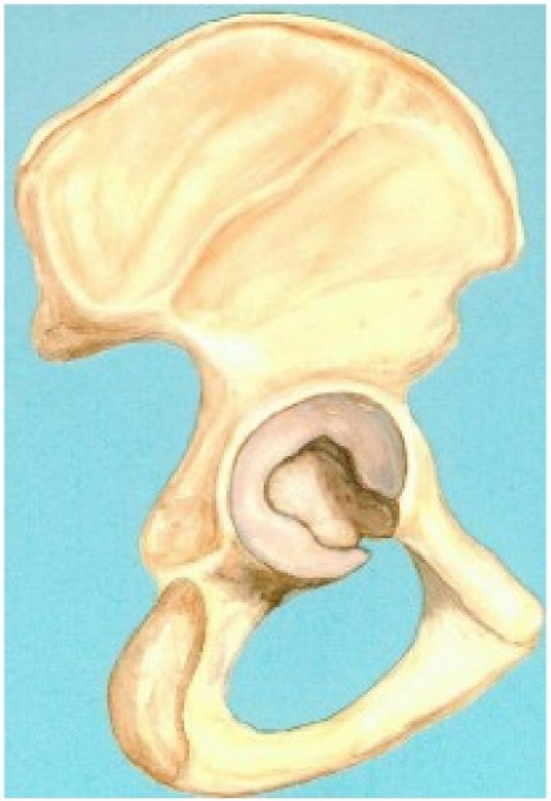

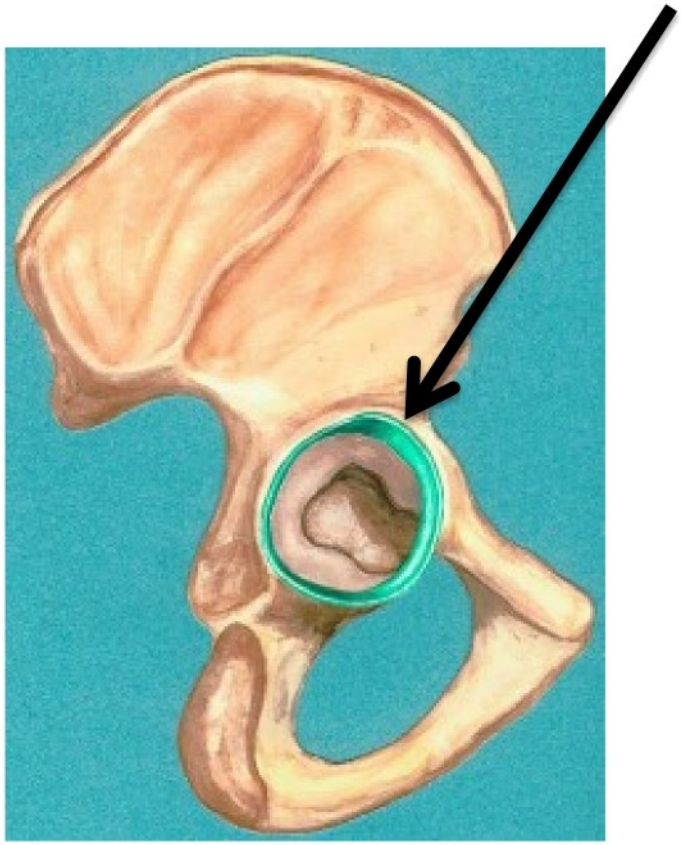

The labrum

- Ring of fibrocartilage
- deepens cavity
- Suction effect

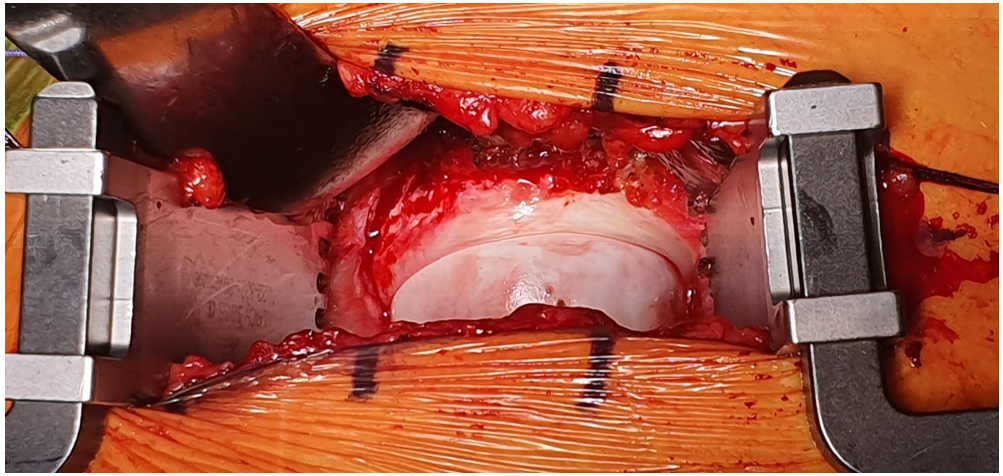

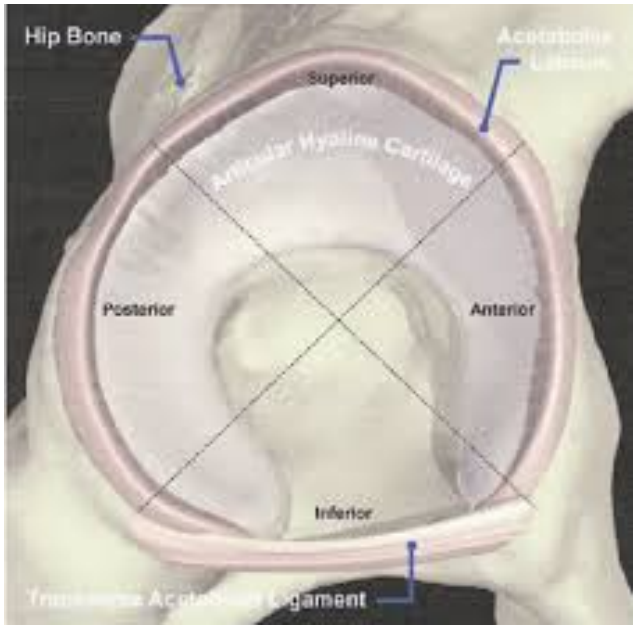

The hip articulation

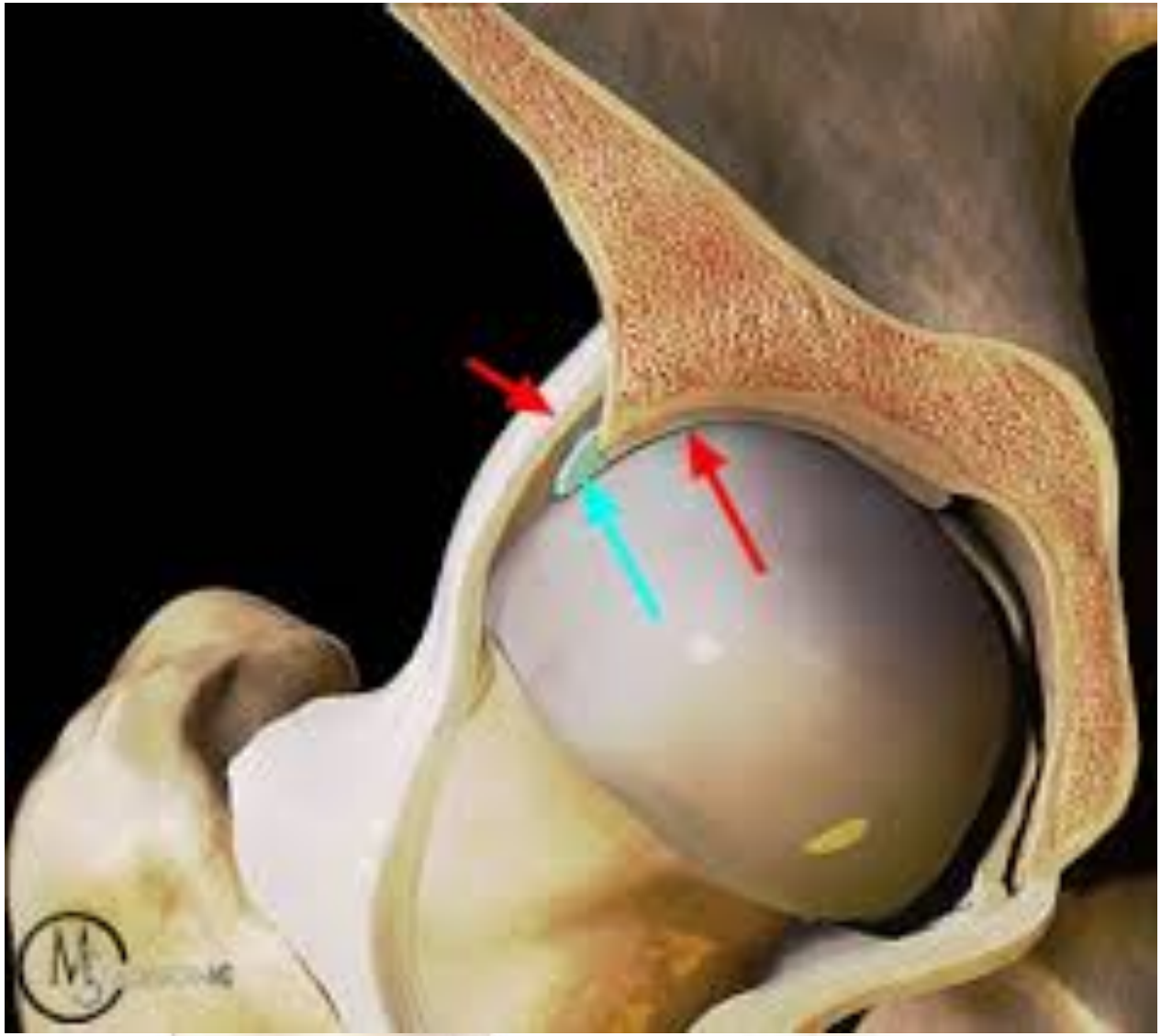

canton de vaud

CHUV

The hip

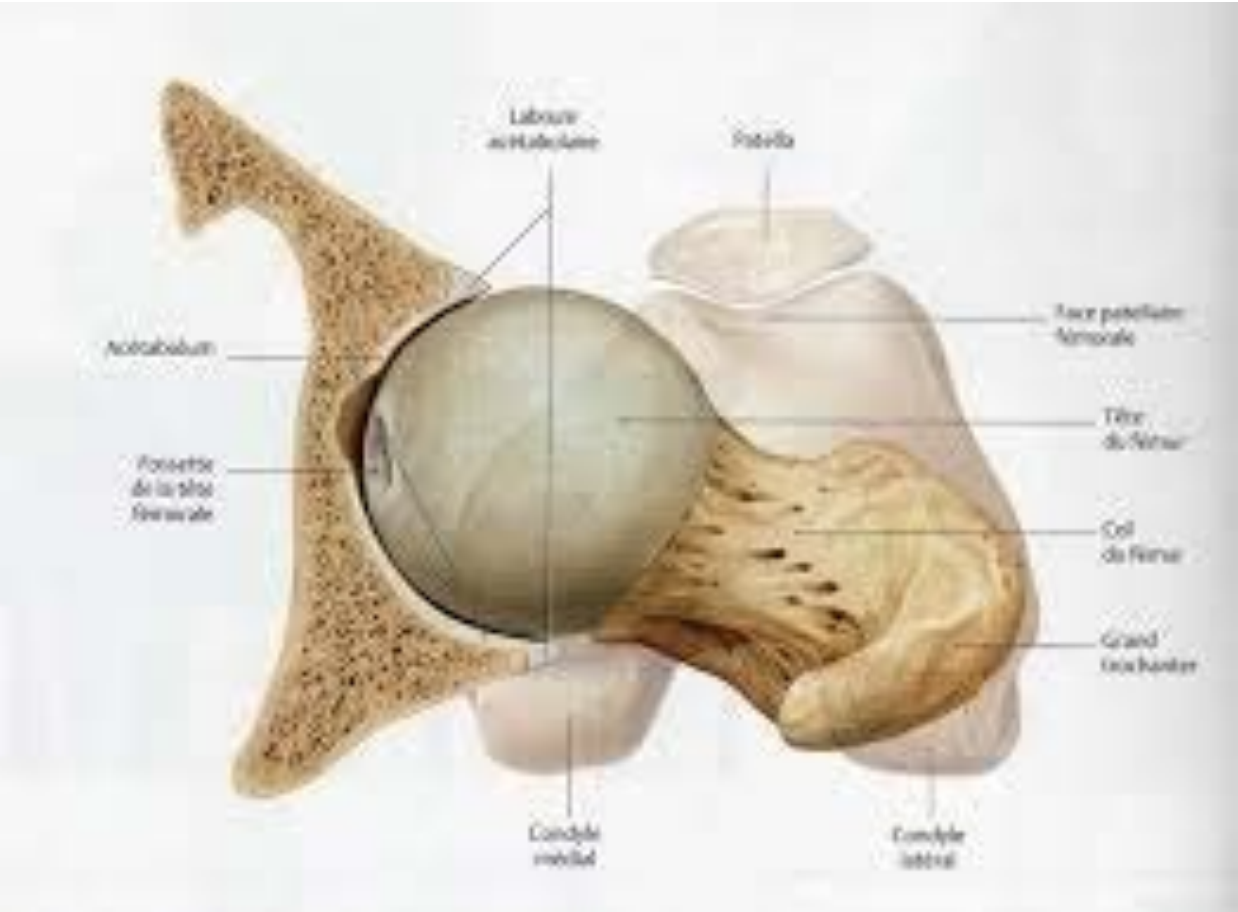

Anteversion of the femoral neck

The hip:

stability

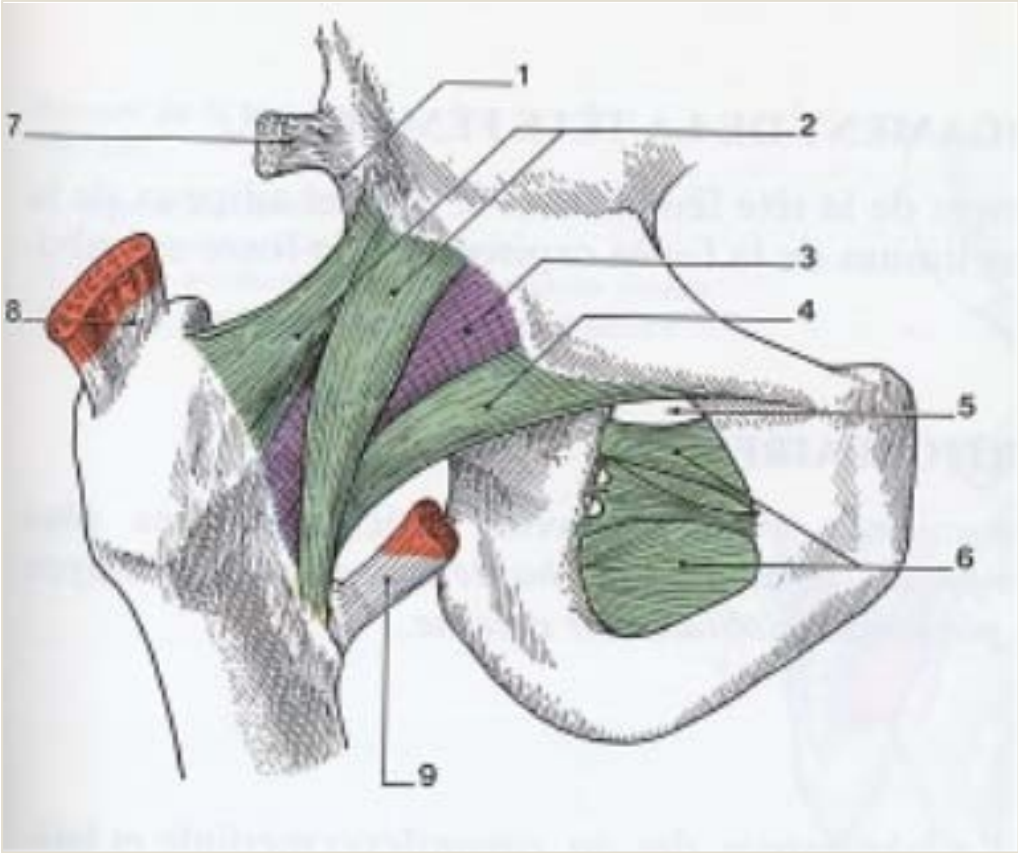

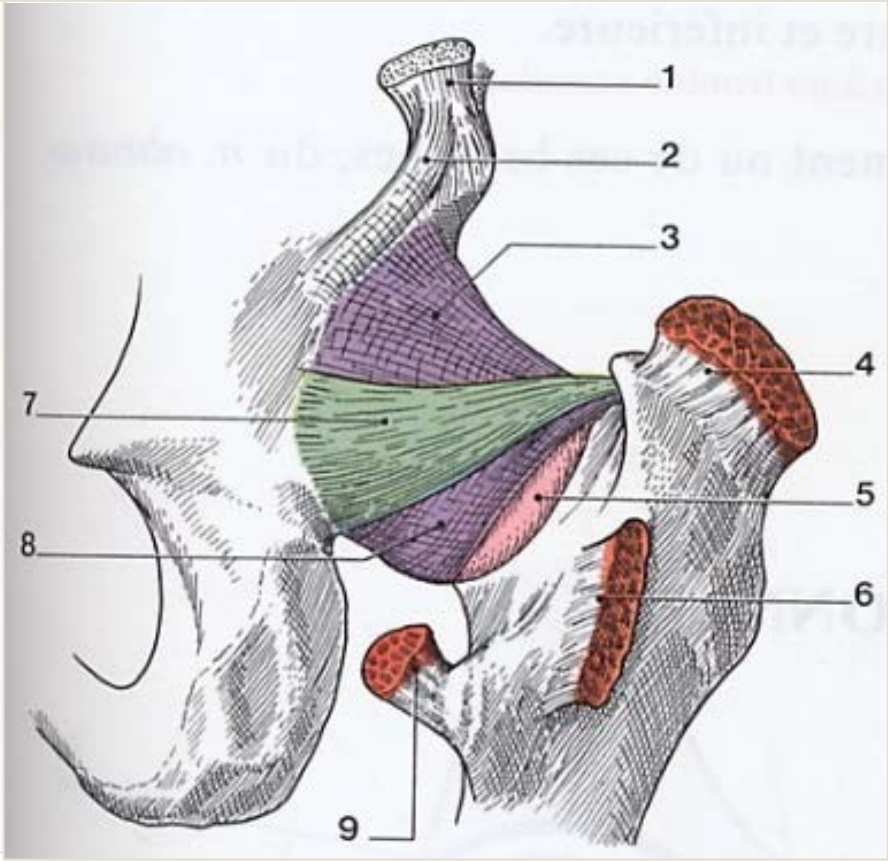

The hip:

stability

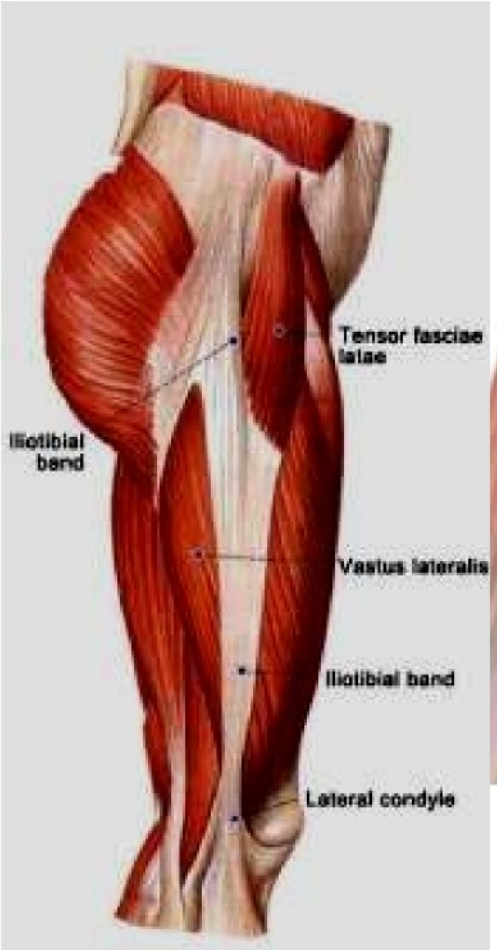

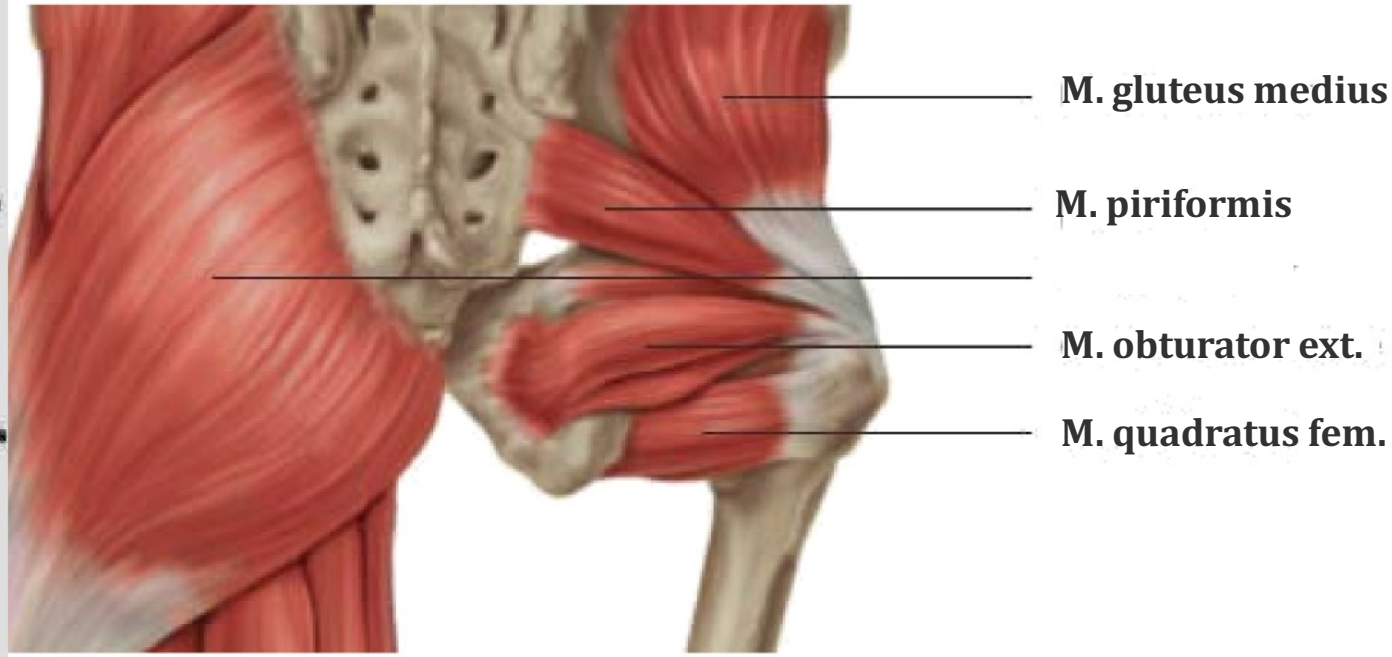

The hip:
mobility

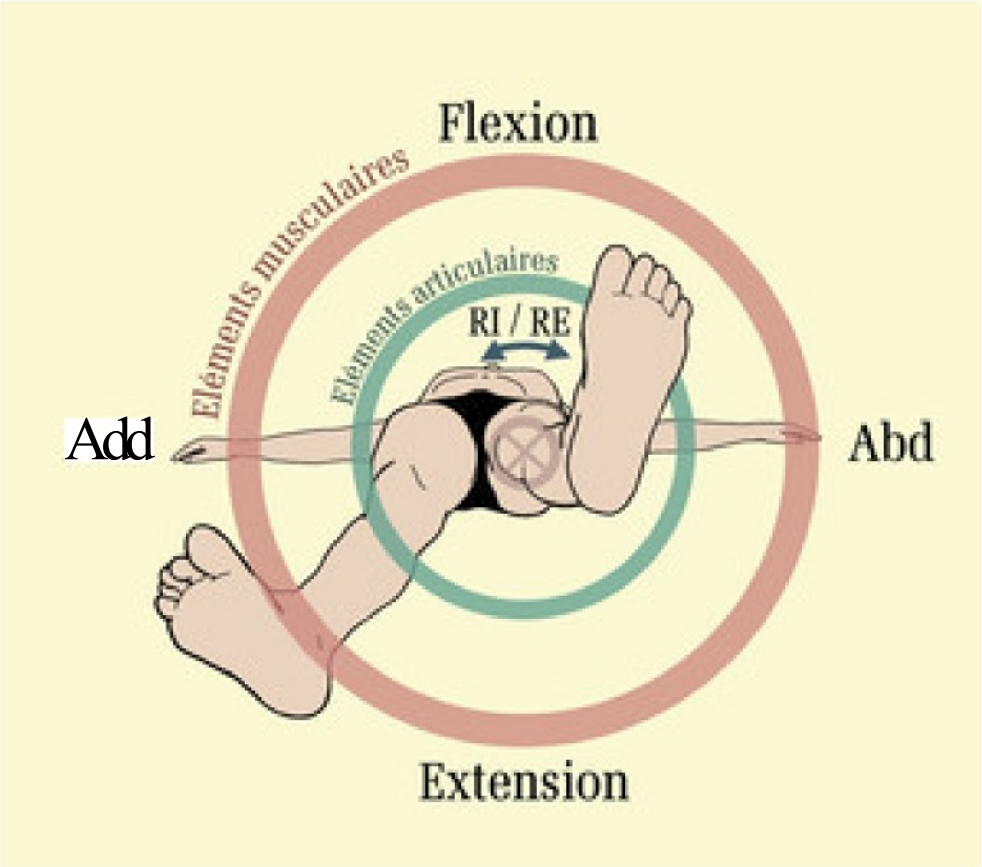

The knee

The Knee

- superficial joint
- stability
- weight bearing articulation

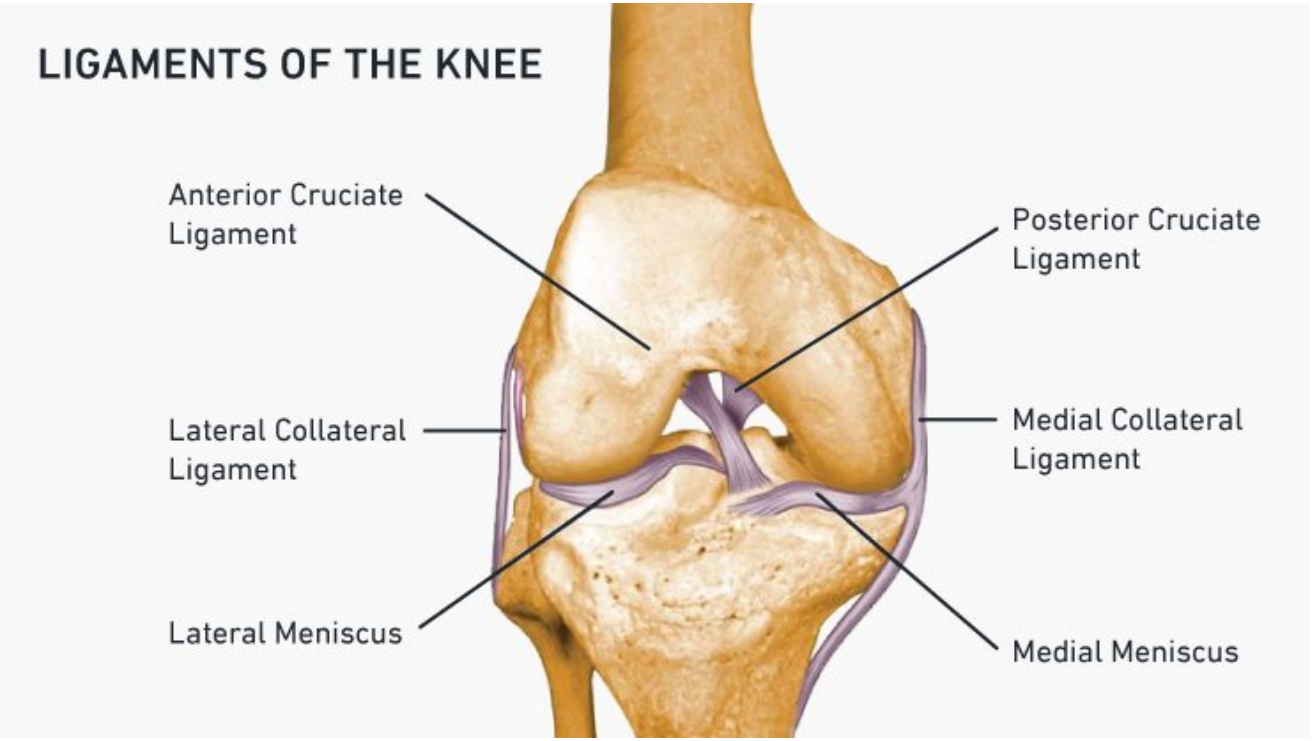

The knee:

Articular surfaces

- Distal femur
  - Femoral condyles

The knee:

Articular surfaces

- Proximal tibial
  - Tibial condyles

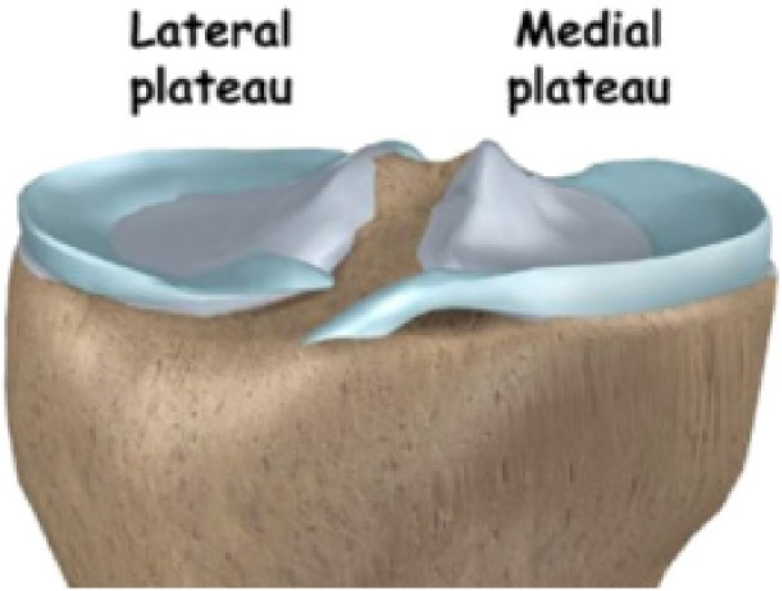

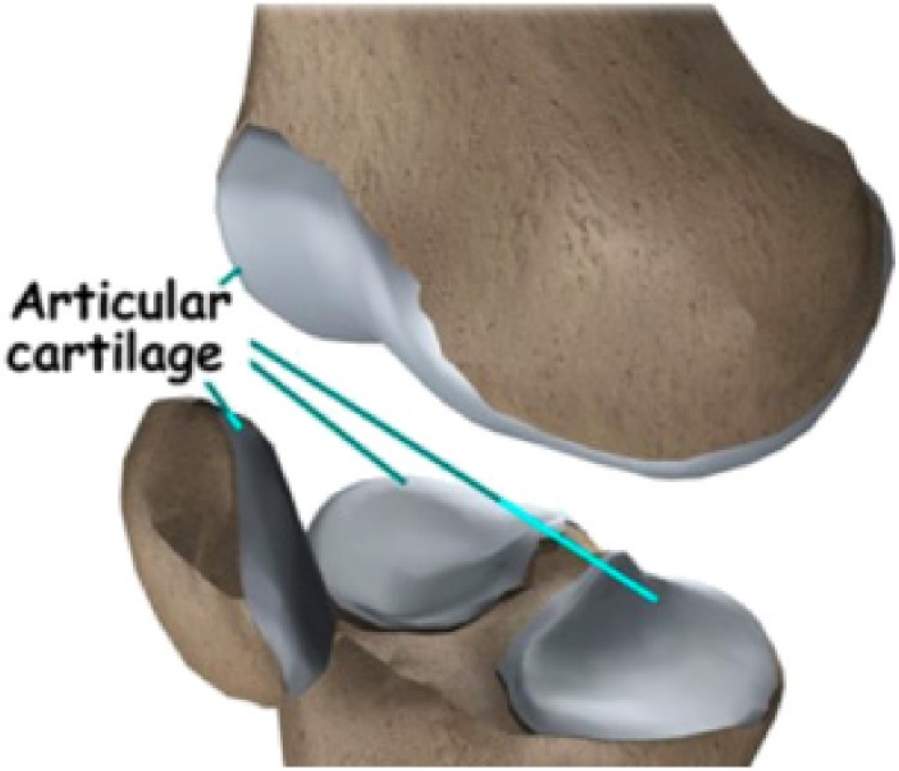

The knee:

Articular surfaces

- Proximal tibial
  - Tibial condyles

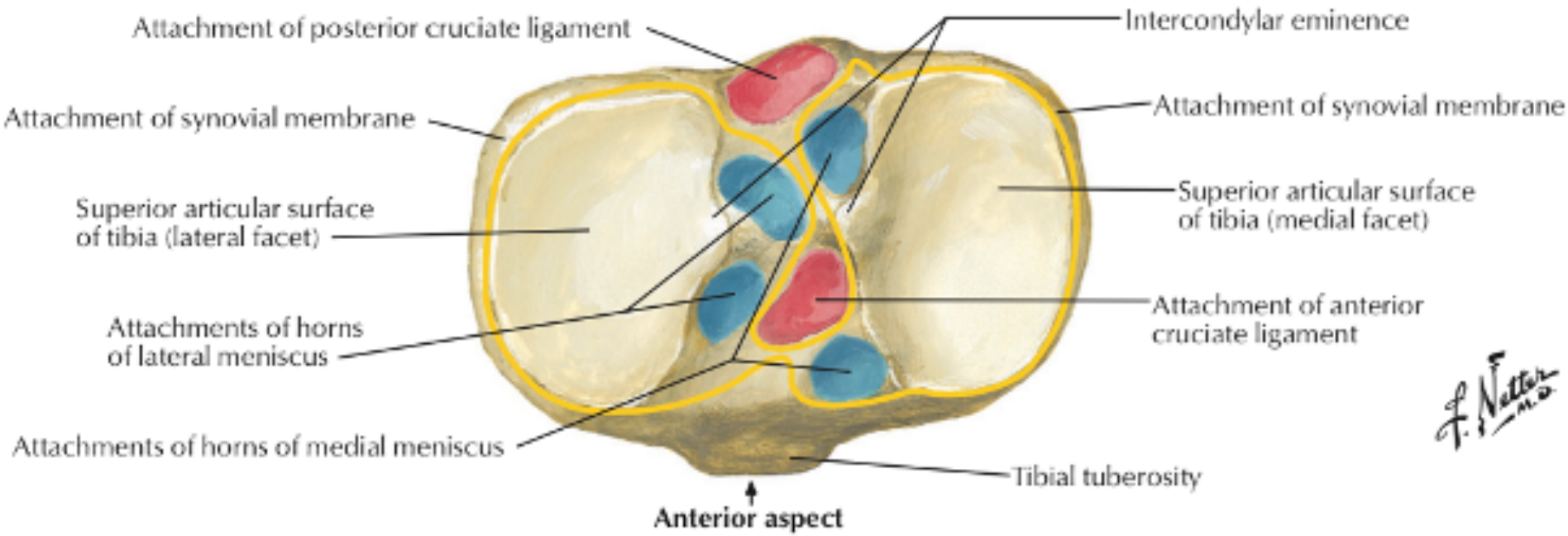

The knee:

Articular surfaces

- Femoro-tibial incogruency

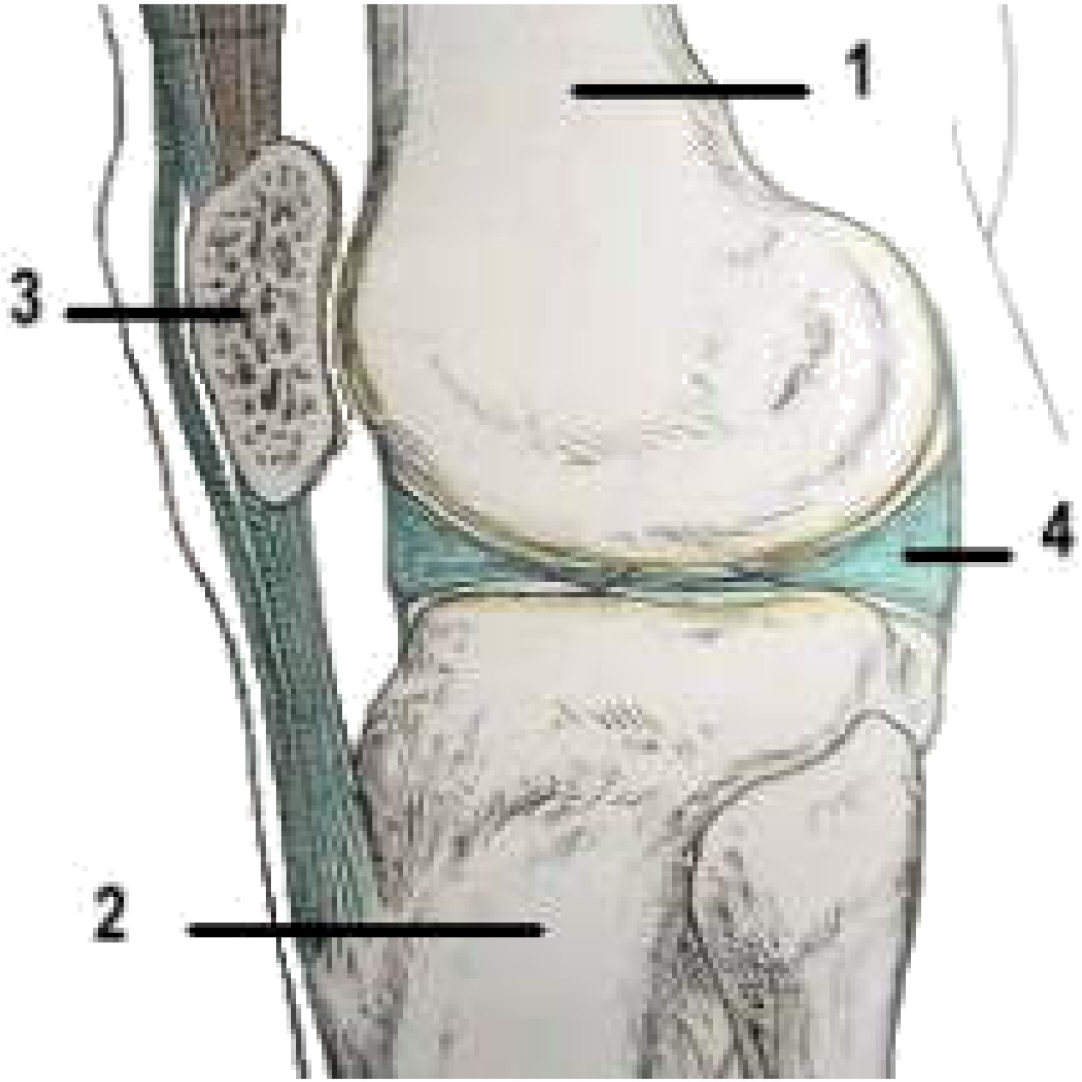

The knee:

Articular surfaces

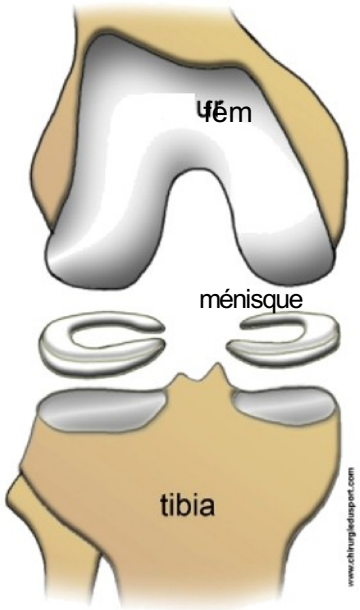

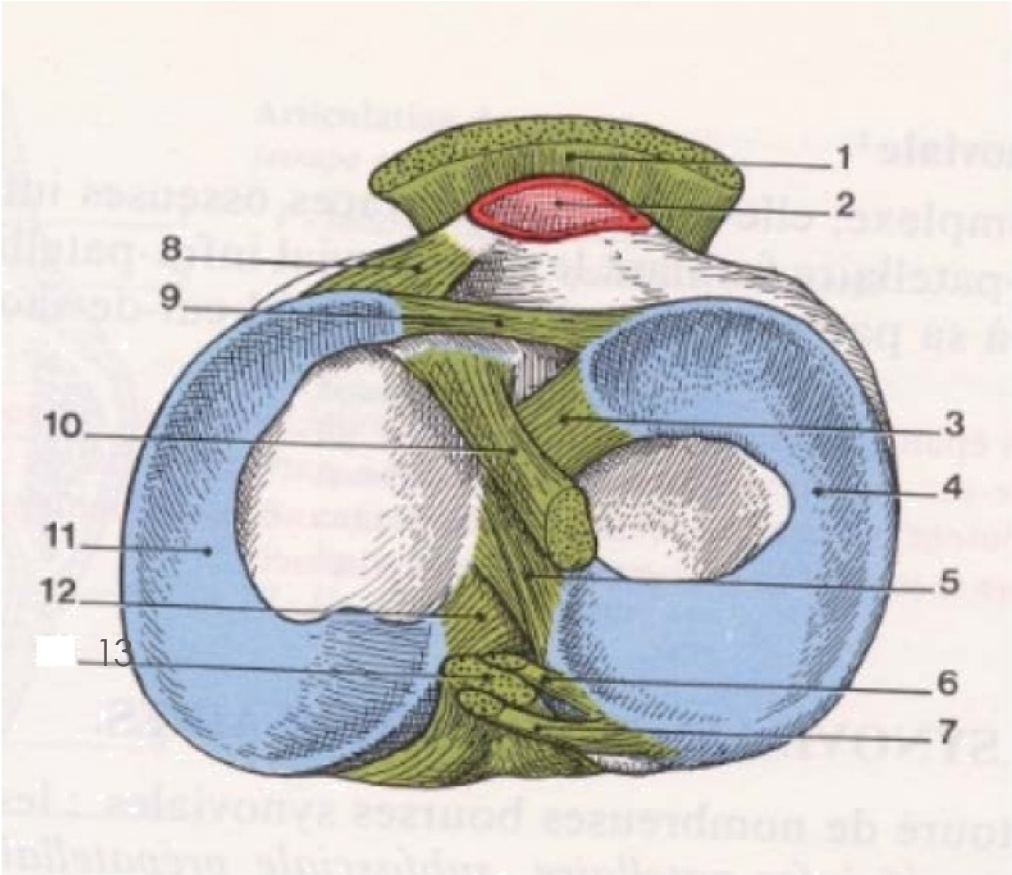

The knee:

Stability antero-posterior

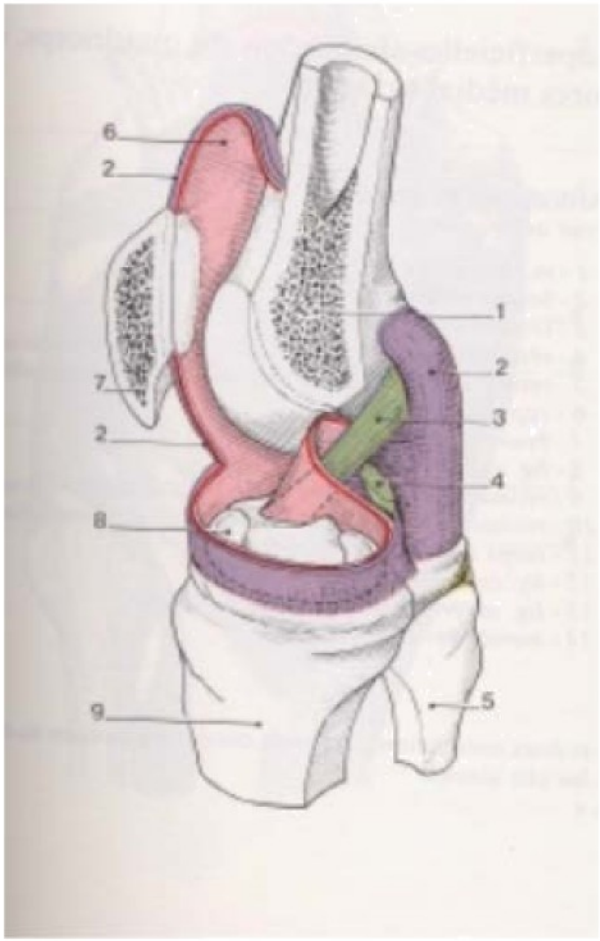

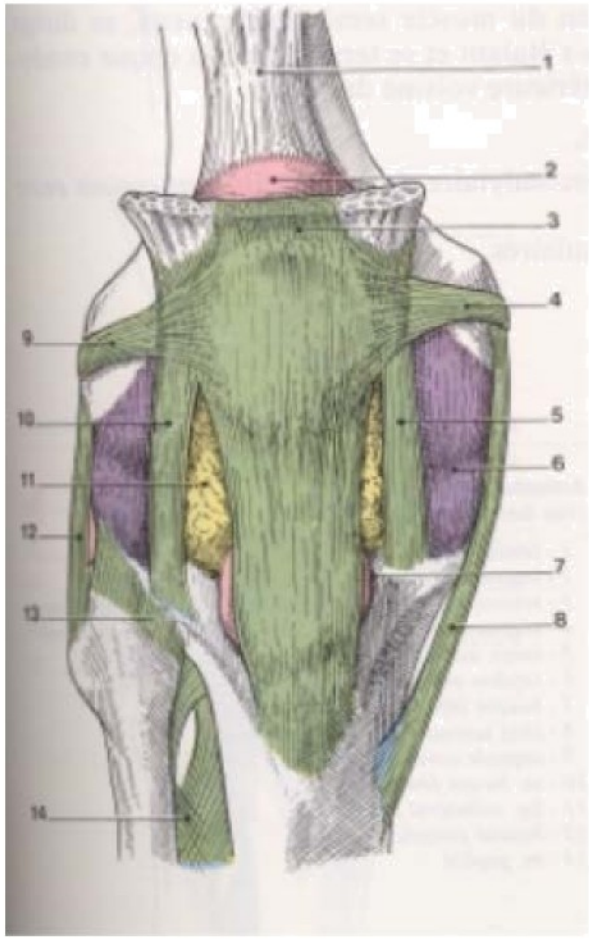

- capsule
- Patellar ligament

Le Genou:

Stability antero-posterieure

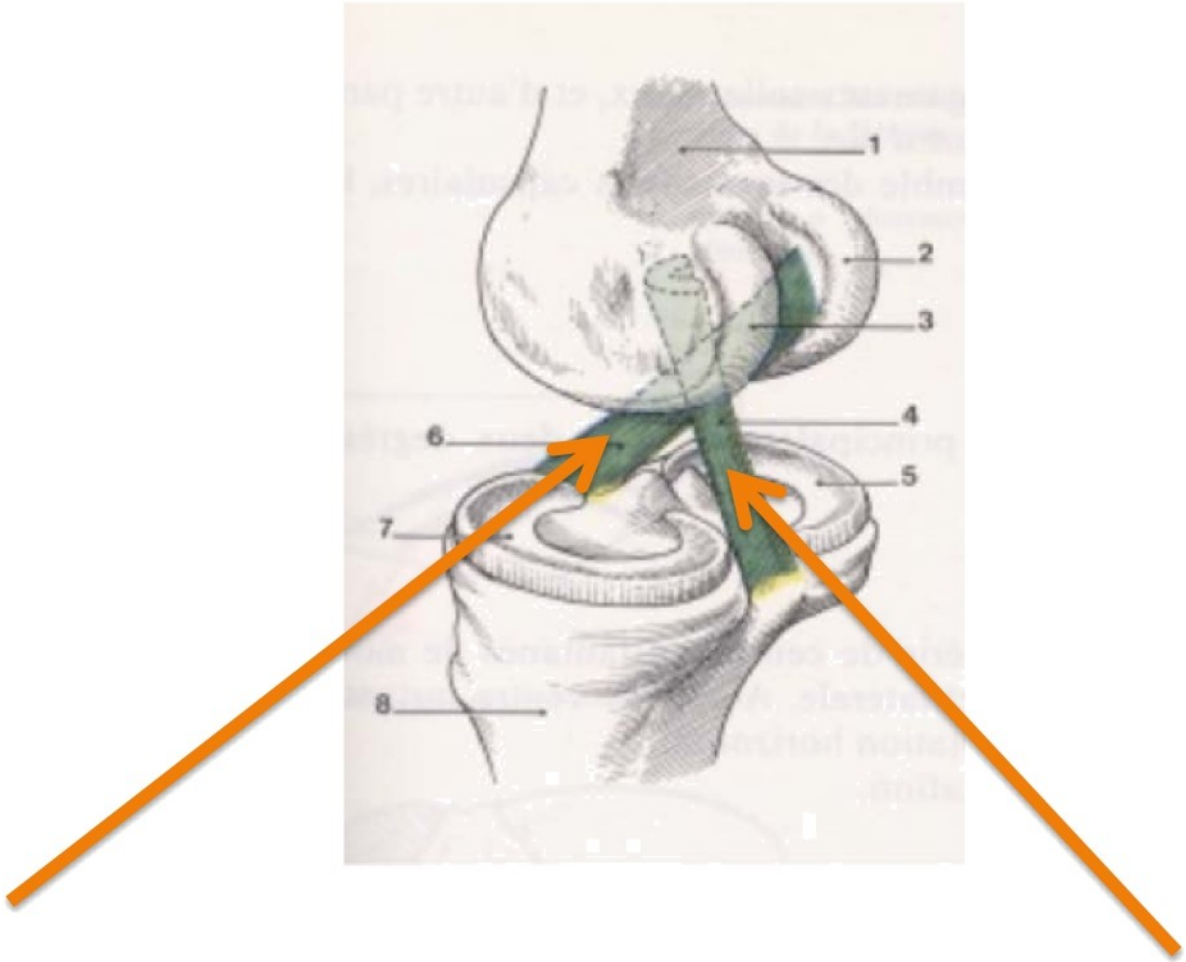

- Lig. cruciate anterior
- Lig. cruciate posterior

The Knee:

Stability frontal

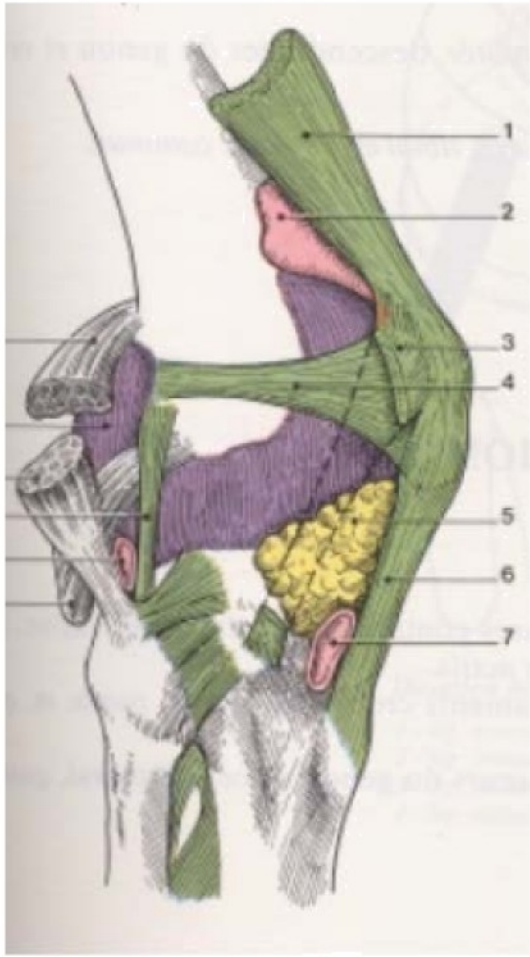

Ligt collatéral latéral

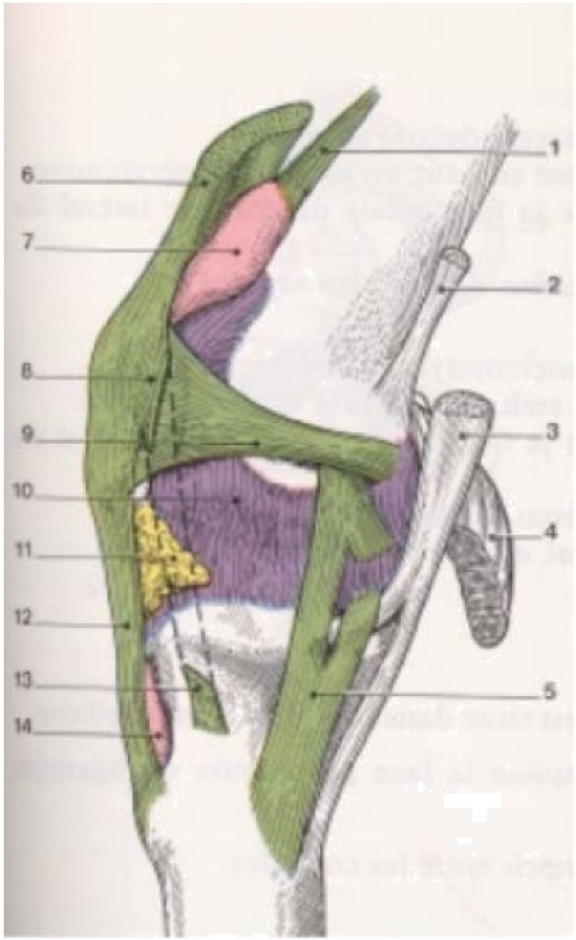

Ligt collatéral médial

The Knee:

Stability frontal

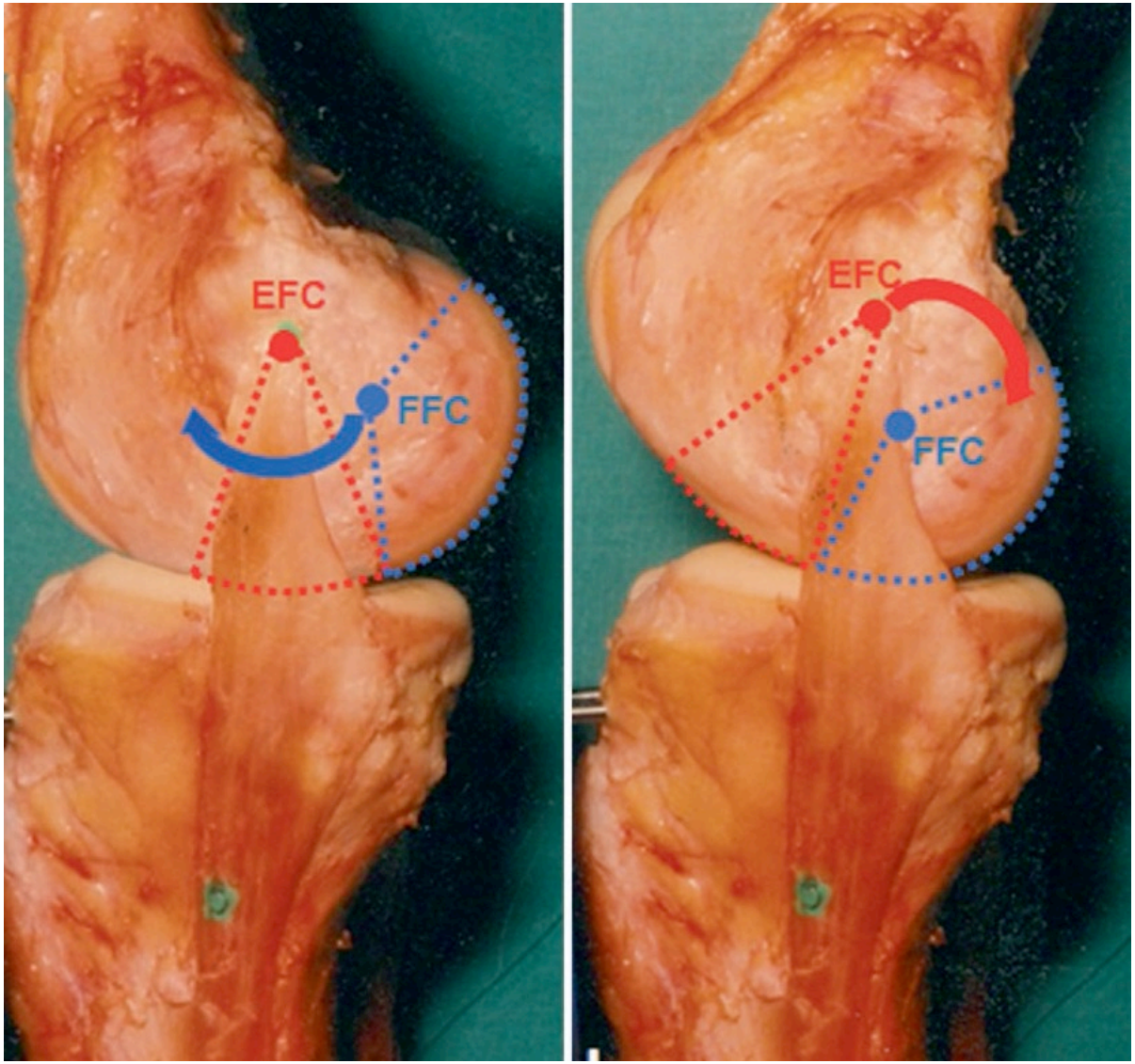

The knee:

mobility

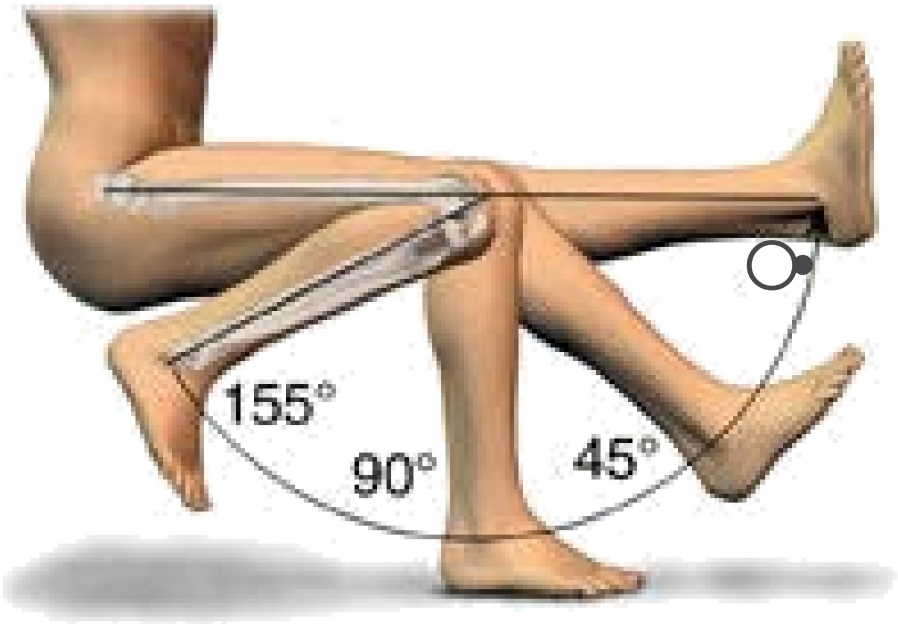

The knee:

mobility

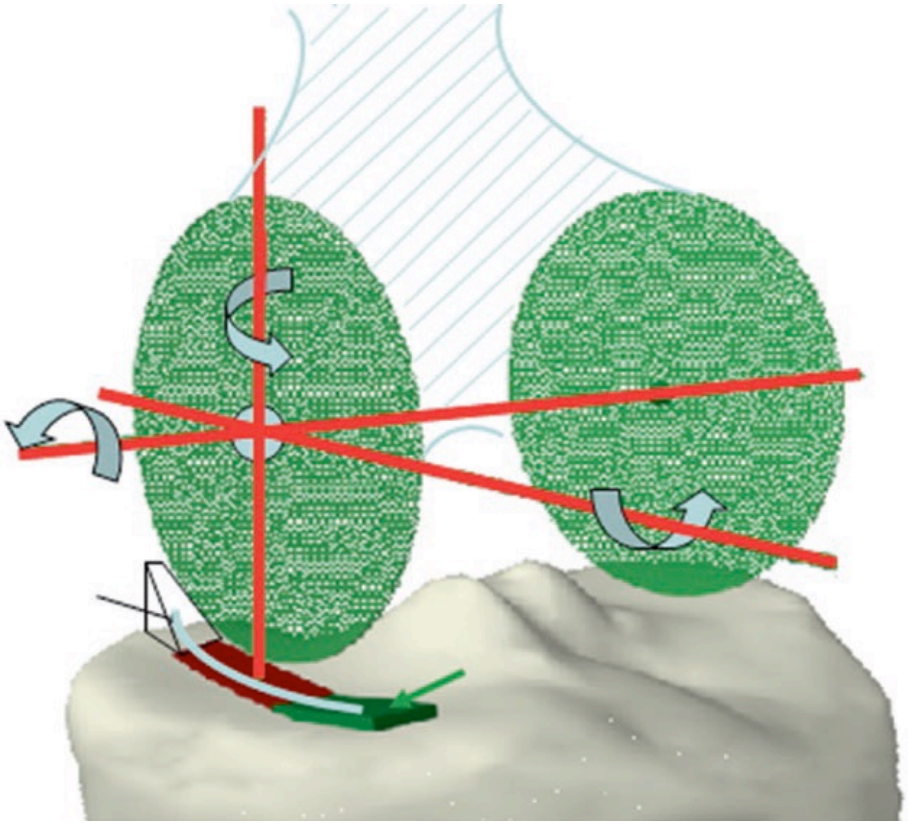

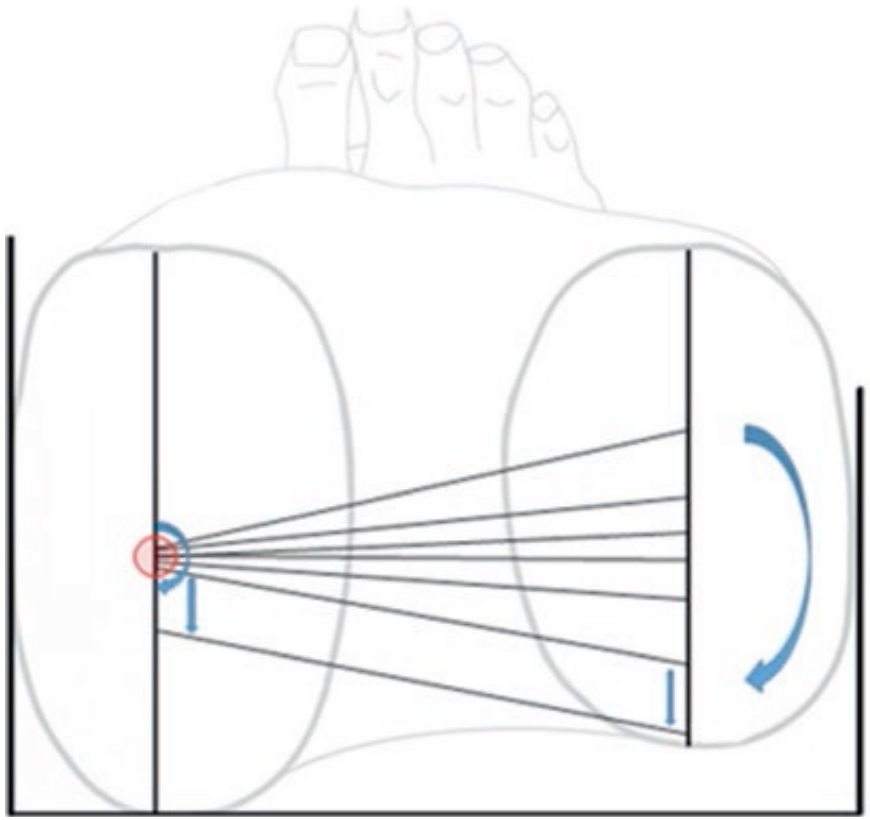

Osteoarthritis

- most frequent musculoscelettal disease
- high morbidity in developed countries
- second cause of invalidity after cardiovascular diseases

The articular cartilage

= hyalin cartilage

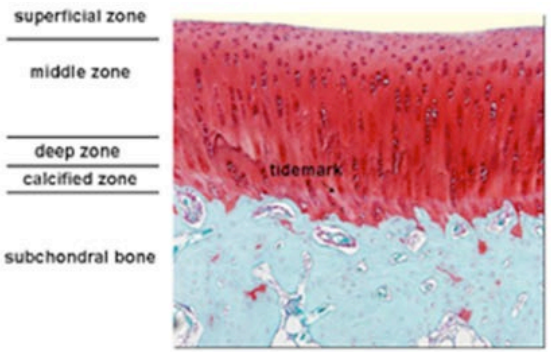

Normal

Osteoarthritis

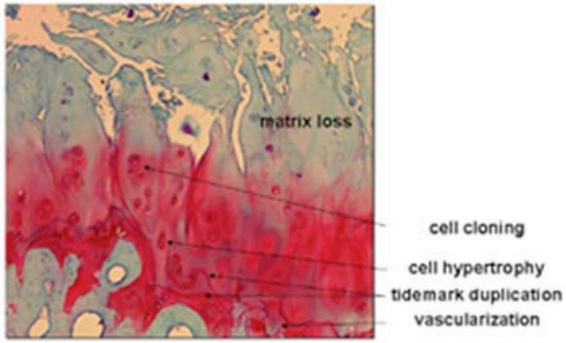

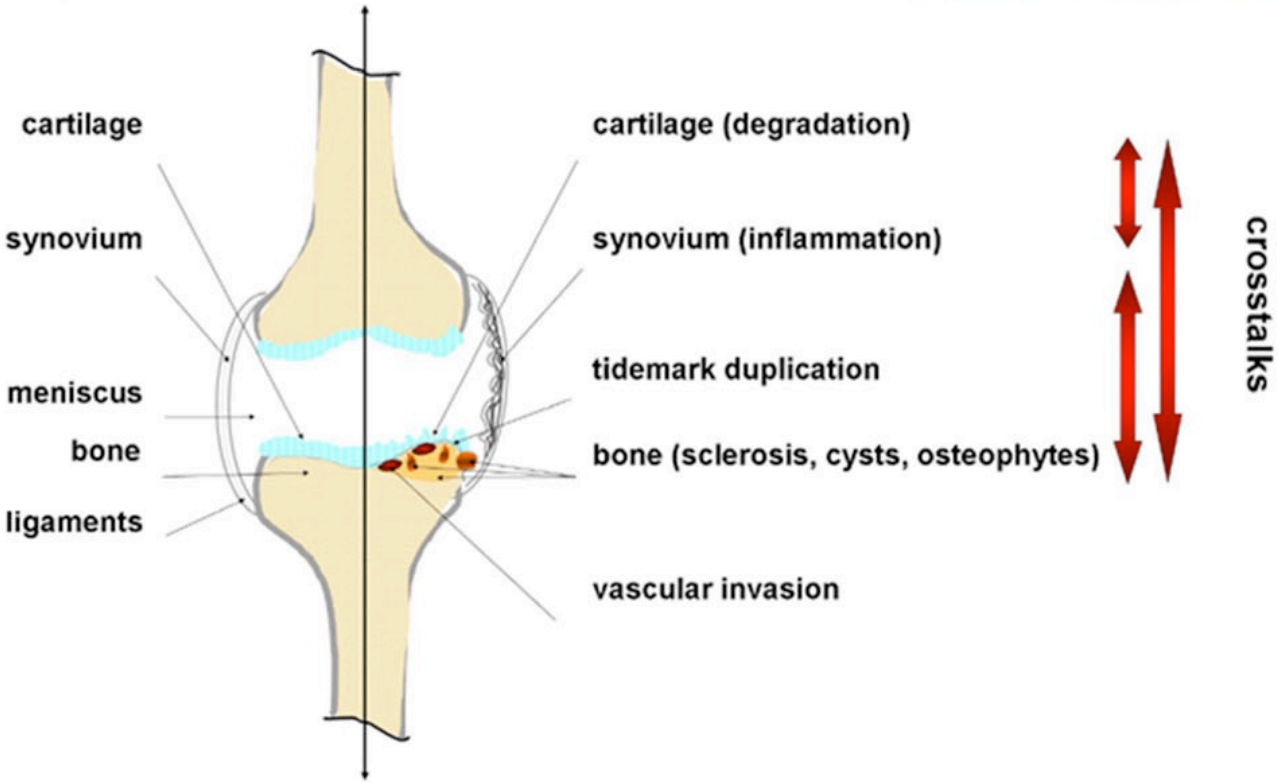

Osteoarthritis :
definition macroscopic & histologic

- Focal alterations of the hyaline cartilage

fissures erosions → subchondral bone

Osteoarthritis :
definition macroscopic and histologic

- Focal modifications of the articular cartilage

fissures

erosions

Exposition of the subchonral bone

Osteoarthritis :
definition macroscopic & histologic

- Modification of adjacent structures

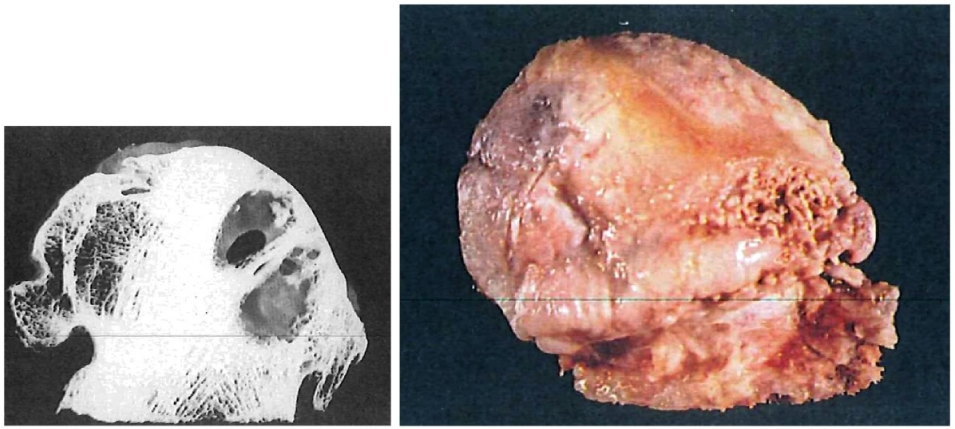

Osteoarthritis :
Definition macroscopic and histologic

- + modifications of adjaecent structures:
  - —Subcondral bone
  - —Synovia

The articulation is affected globally

Osteoarthritis (OA) : classification

- Topographie : Coxarthrosis (hip)
  Gonarthrosis (knee)

All the articulations can be affected by OA!

+/-

- Causal reasons:

— primary OA

— secondary OA

Osteoarthritis of the hip

COXARTHROSIS

- The most coomon reason of a chronic coxodynia (>6 mois)
- Disease of the articulation:
  - Wear of the articulation by progressive destruction of the cartilage
  - secondarily, unspecific synovial reaction and alteration of the subchondral bone

➡ *Bone remodeling on the weight-bearing zone*

Primary OA of the hip

- Estimated prevalence: 5 - 10 % >55 ans
  - —mean age: 61 ans
  - —bilateral: 40 —50%

COXARTHROSIS :

- Biomechanical factorts
  - Obesity
  - Conflit fémoro-acétabulaire

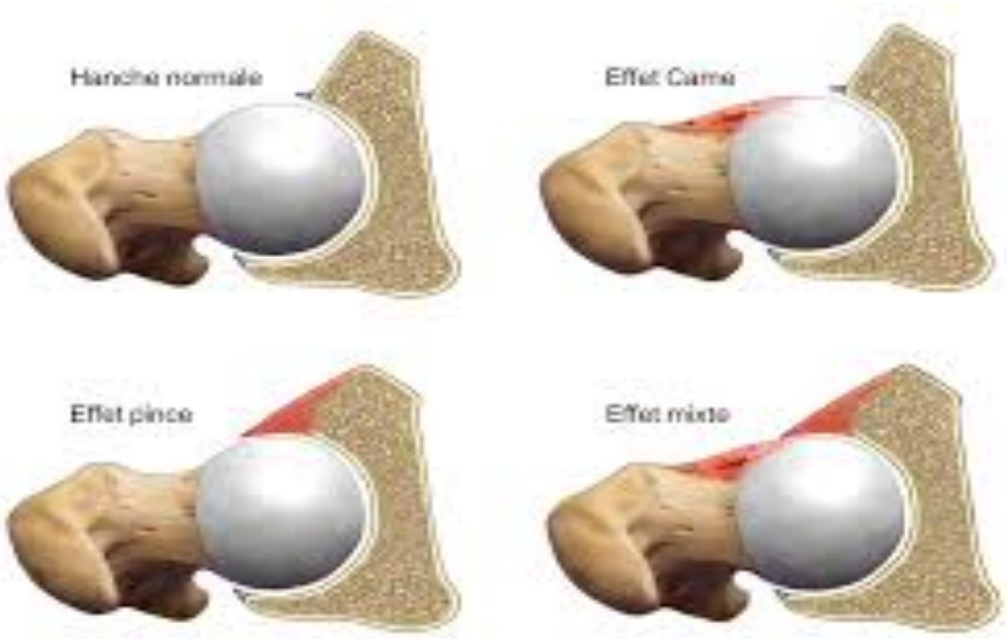

COXARTHROSIS :

- Biomechanical factors
  - Professional and athletic activity

COXARTHROSIS

- Clinical signs :
  - — mechanical pain (typically anterior)
  - — functional impairement:
    - limping
    - restriction of mobility

NO direct radio-clinical correlation

COXARTHROSIS : diagnostic

- The most common symptoms include:
  - —pain
  - —stifness
  - —age > 40 ans
  - —onset progressiv
  - —mechanic character

Diagnostic radiologic :

- ***Signes Rx:***

1. Joint space narrowing
2. sclerosis
3. Bone cysts
4. osteophytes

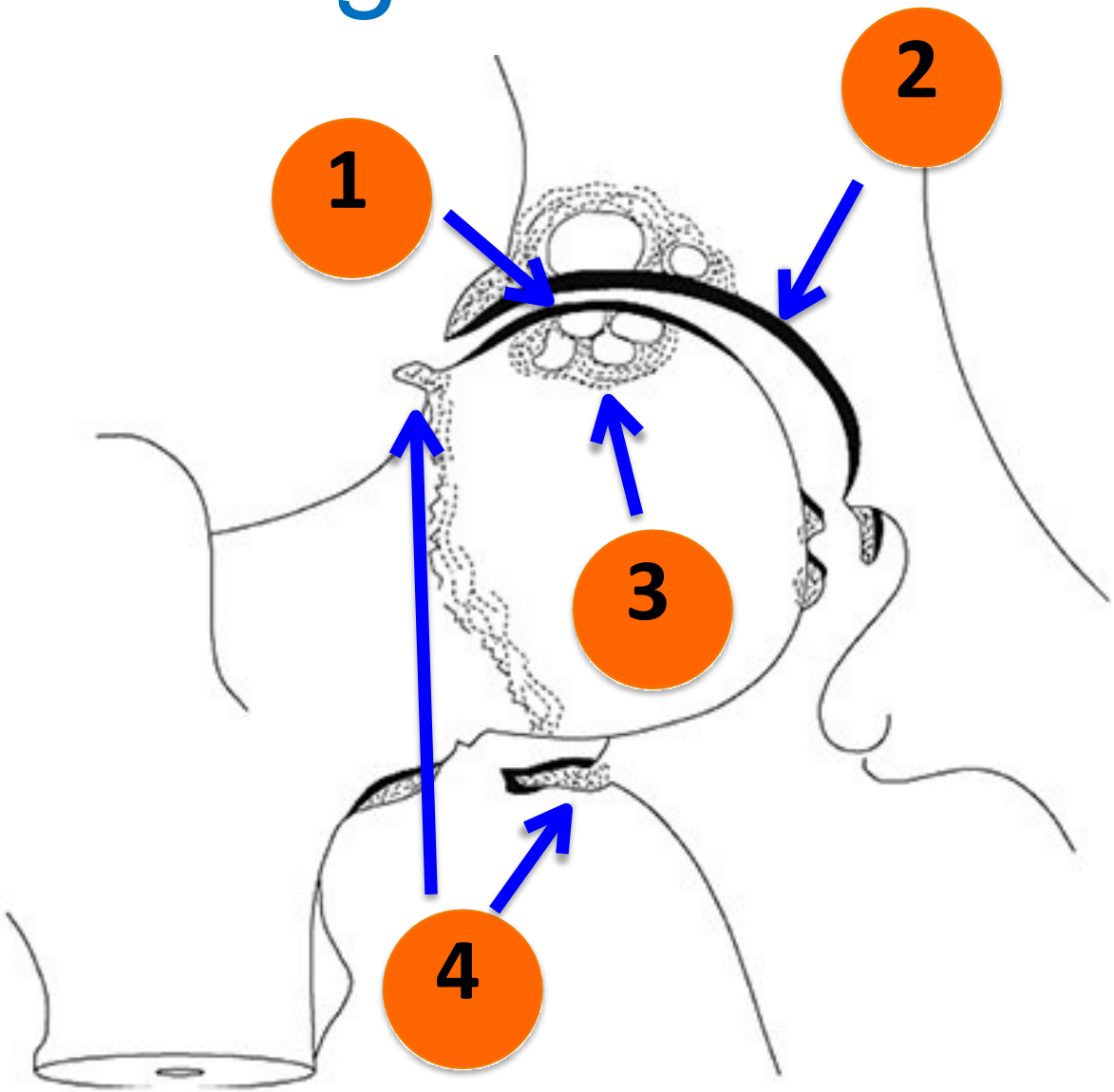

Diagnostic radiologic :

- ***Signes Rx:***

1. Joint space narrowing
2. sclerosis
3. Bone cysts
4. osteophytes

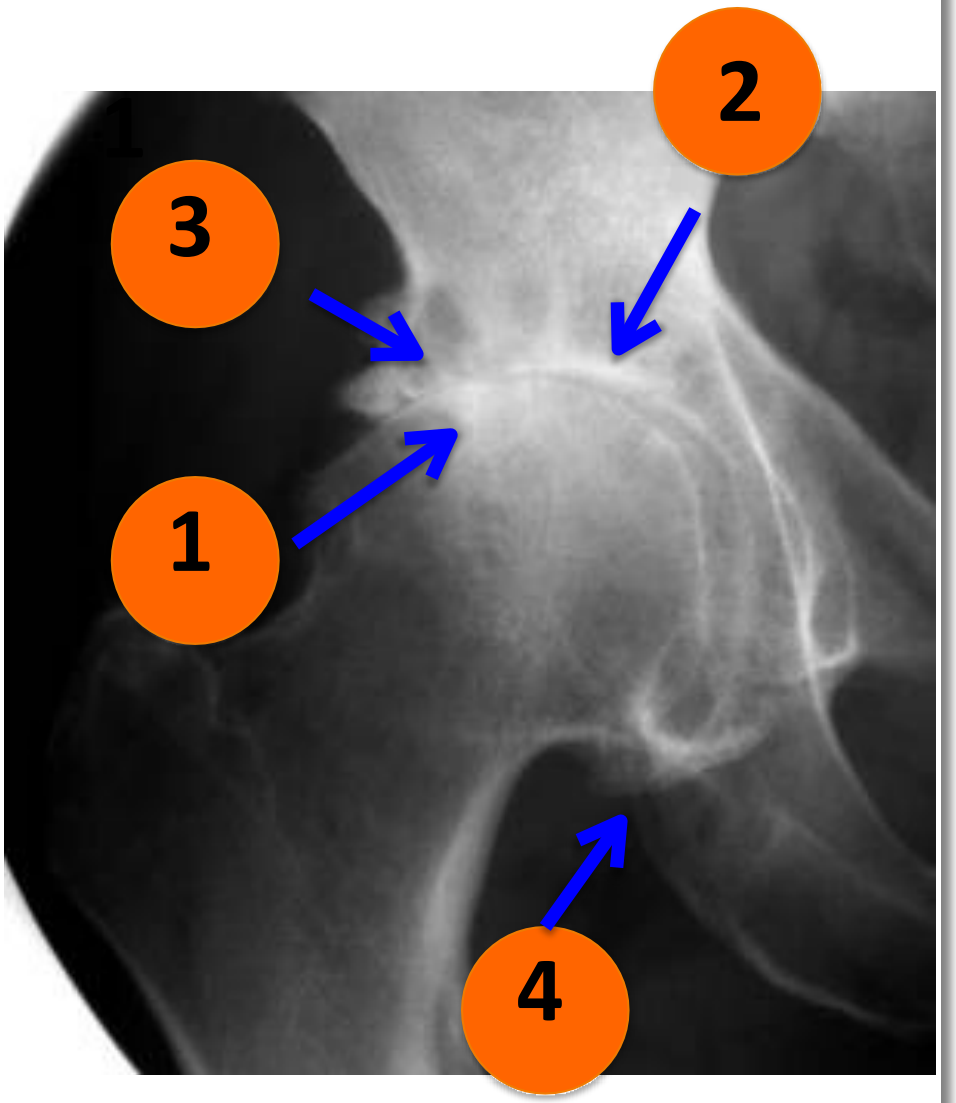

Analysis Rx : Dg etiologique coxahrosis secondary

- Coxometrie : Hip dysplasia ?

Other secondary reasons:

- Avascular necrosis
- Post-traumatique
- Sequels of ostéochondrite
- Sequels of epiphysiolysis
- Sequels of septic arthritis

Analyse Rx : coxometrie

Femoral neck-shaft angle :

Caput-collum-diaphyseal **angle** (**CCD angle**)

The **angle** between the longitudinal axes of the **femoral** neck and shaft

Normal values of CC'D:

- 125-130^0

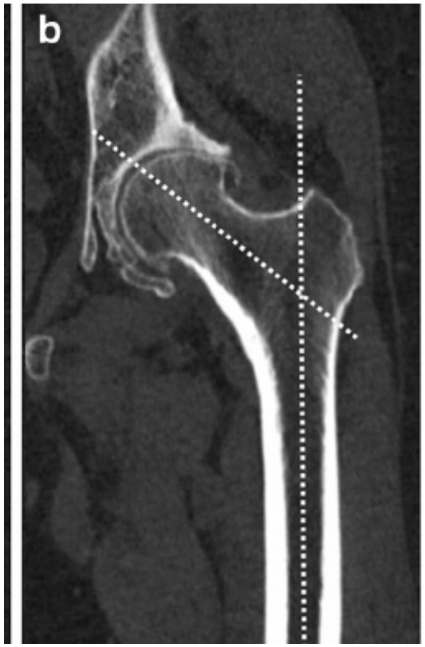

$125^0 < N < 135^0$

Anaìyse Rx : coxometrie

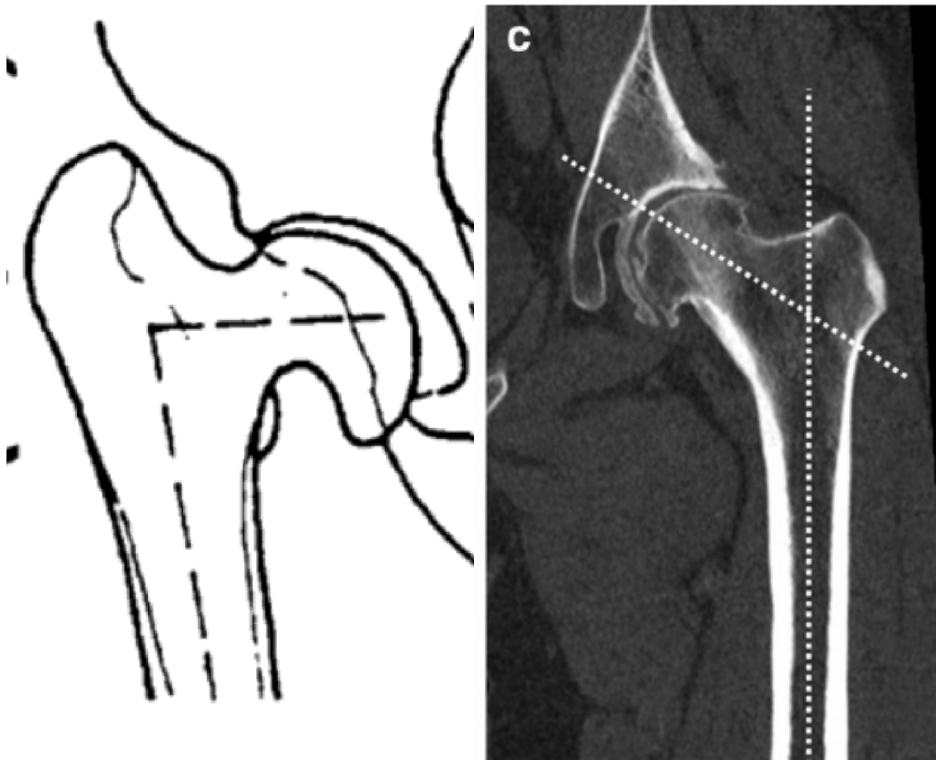

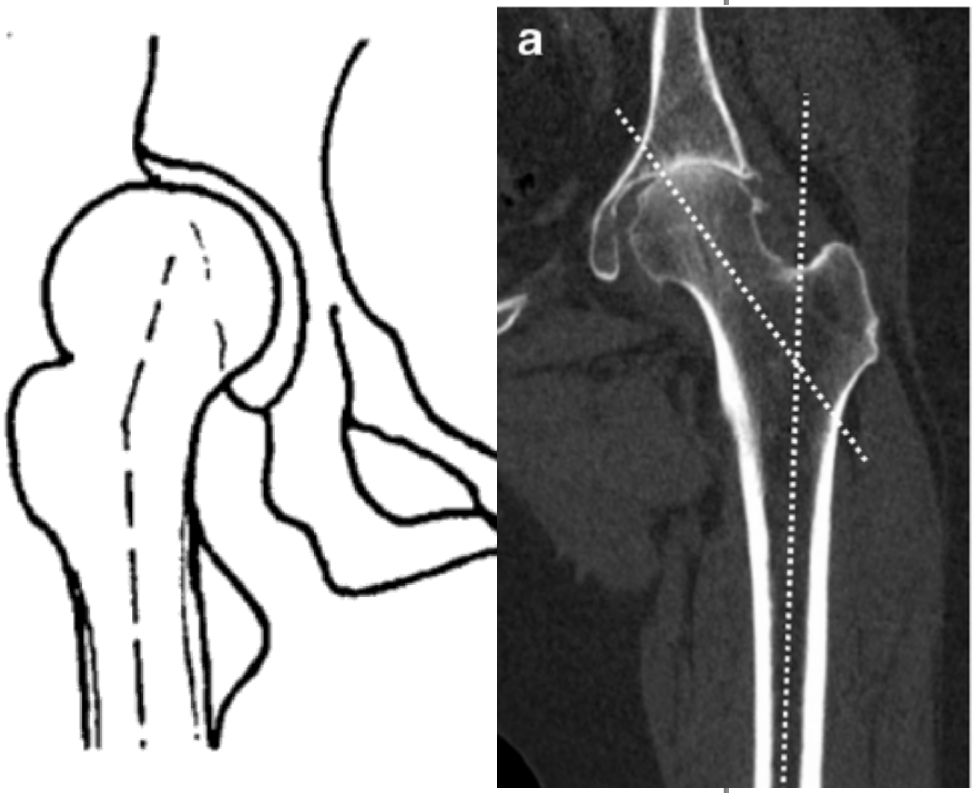

< 125° COXA VARA

> 135° = COXA VALGA

Anaiyse Rx : coxometrie

Coverage of the femoral head:

Angle between the center of femoral head and lateral acetabular border

Wiberg or CE (center-edge) angle

Normal value: 25-35°

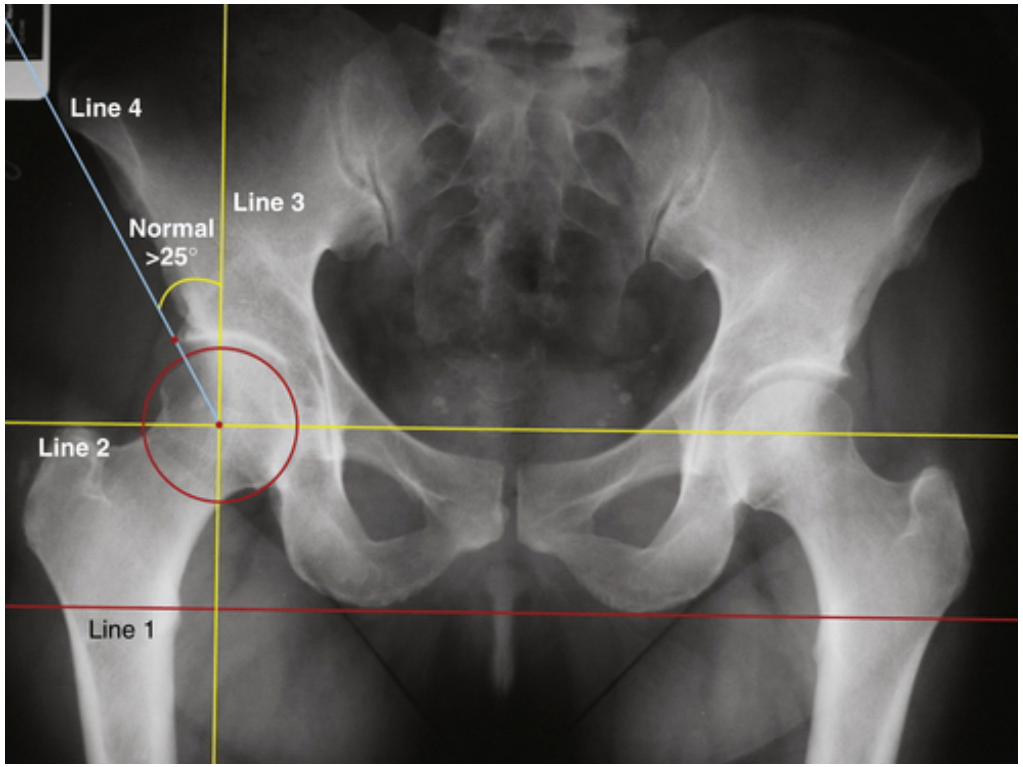

Analysis Rx : coxometrie

Anterior coverage angle*:*

False profile view of the hip

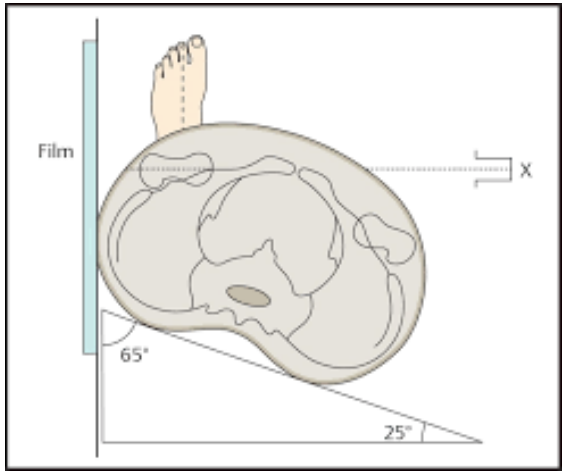

- angle between the center of the femoral head and the anterior-most aspect of the acetabulum

Analysis Rx : coxometrie

Acetabular index (Tönnis angle)

radiographic measurement of femoral head bony coverage by the acetabulum

- decreased: <3°
  - in severe overcoverage, there may be a negative value
- normal range: 3-13° [2]
- increased: >13°
  - in acetabular dysplasia

Coxometrie : structural anomaly ?

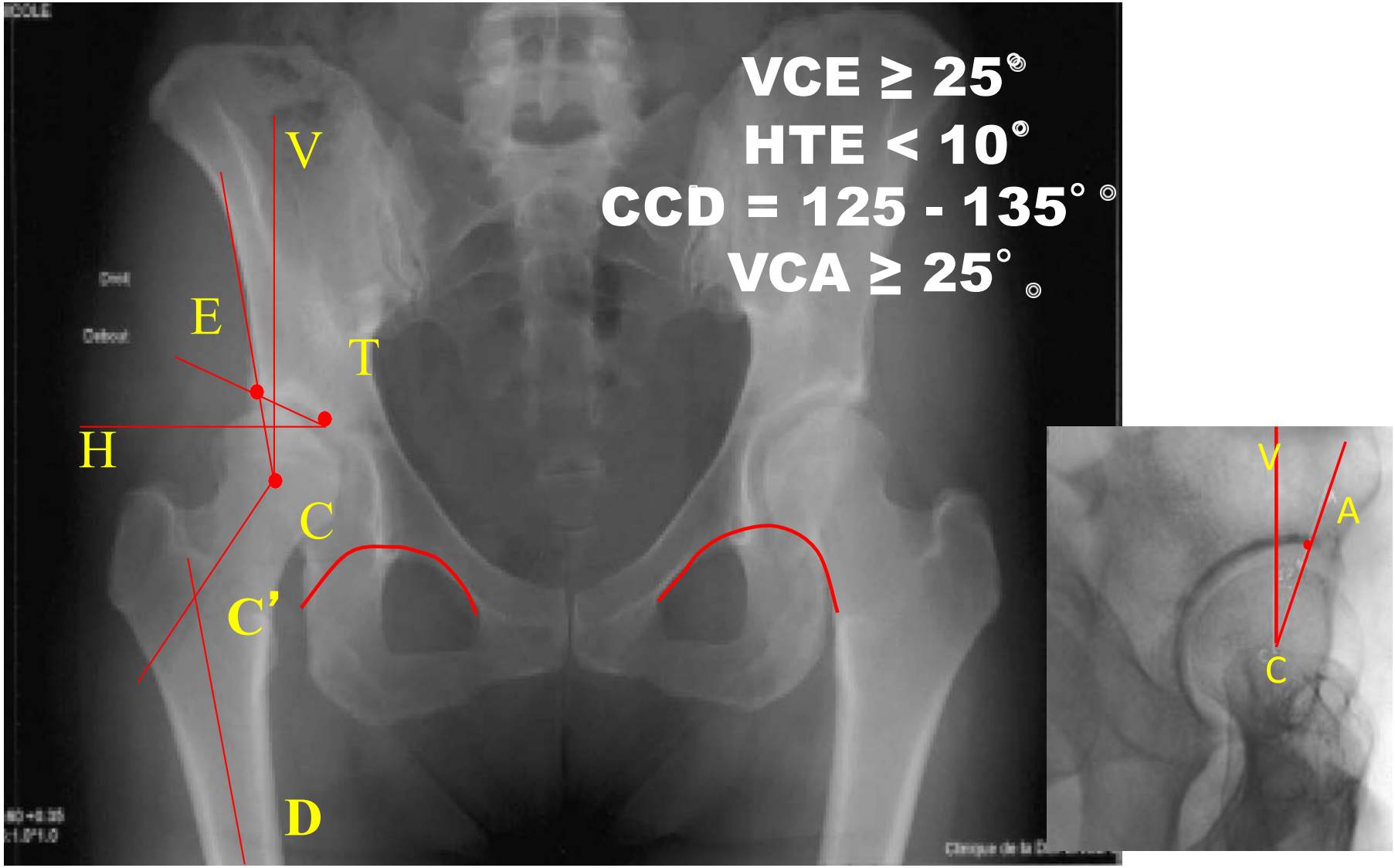

Anomalie architecturale = coxarthrose secondaire

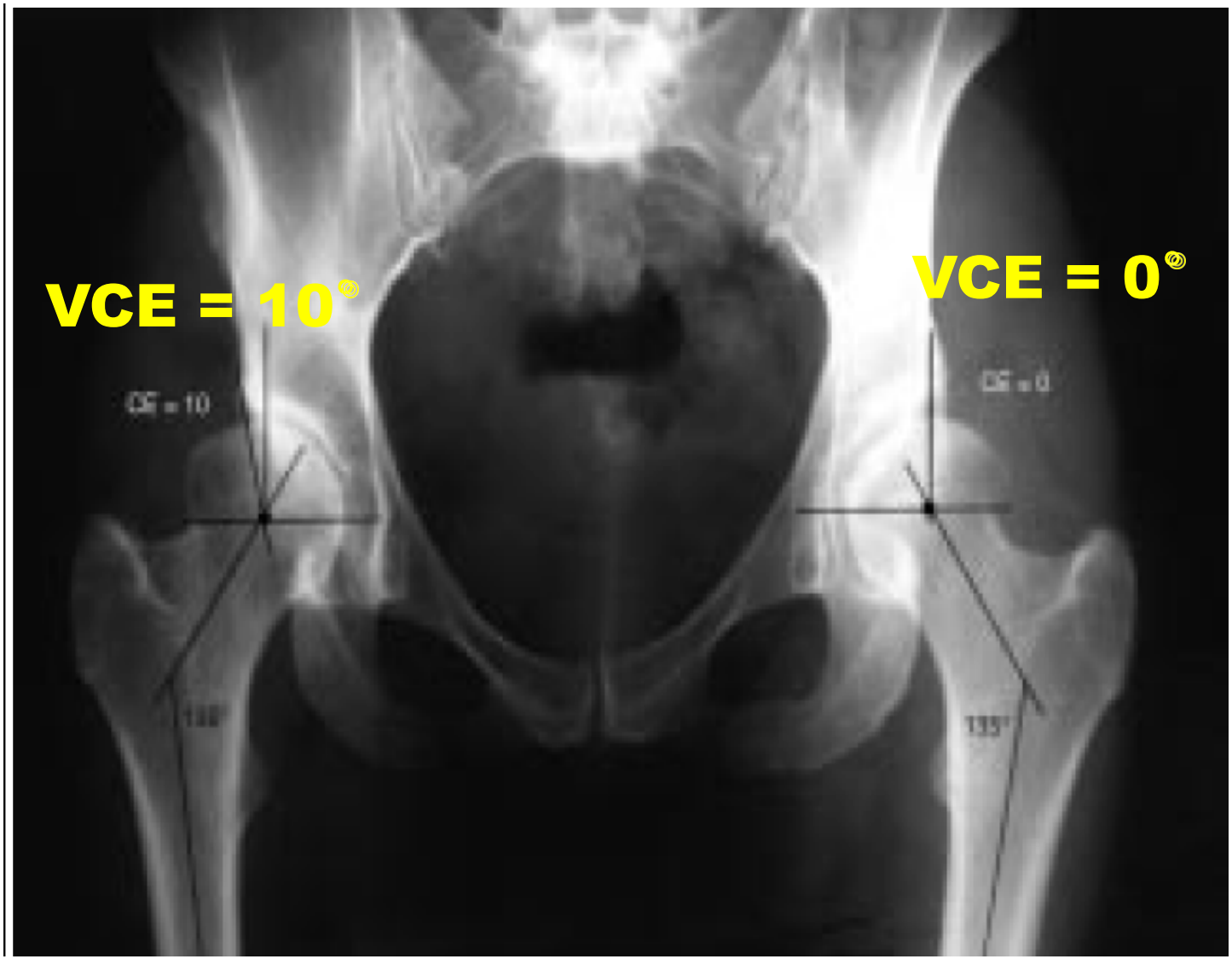

Anomalie architecturale = coxaûhrose secondaire

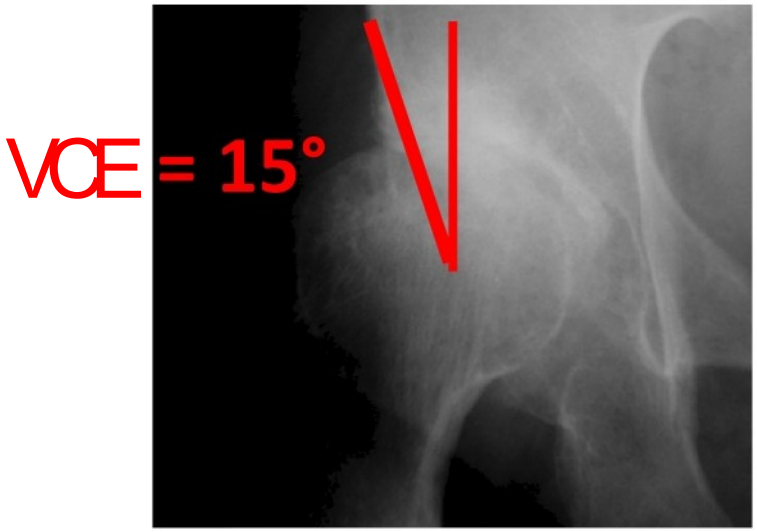

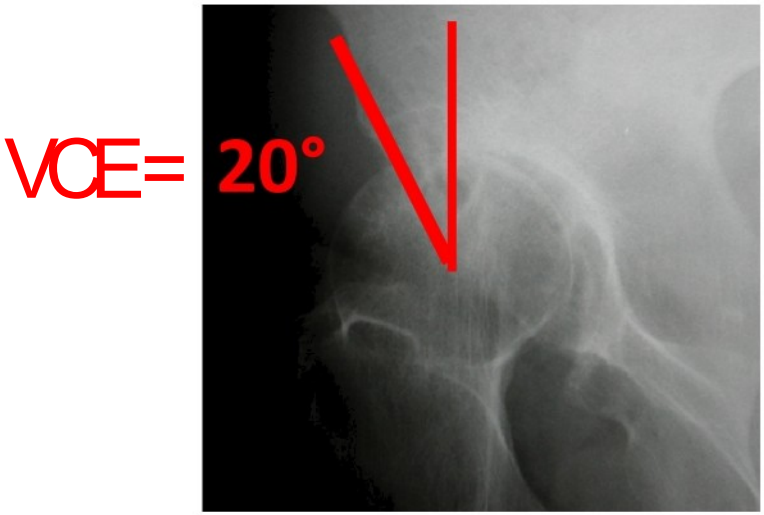

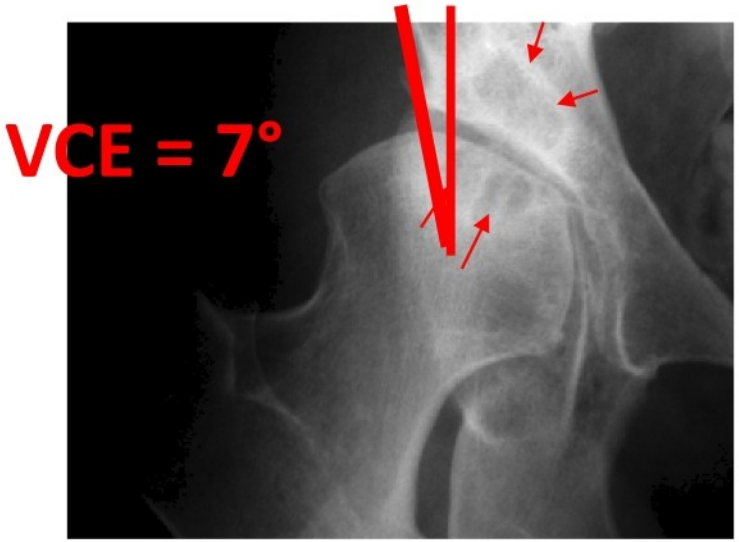

COXARTHROSIS : Traitement

- Therapeutic strategy:

Is the cause of coxarthrosis correctable ?:

- *dysplasia* or *congenital dislocation*

  Hip conservative surgery:

  âge <45 ans, optimal conditions

COXARTHROSIS : Traitement

Peri-acetabular osteotomy (PAO)

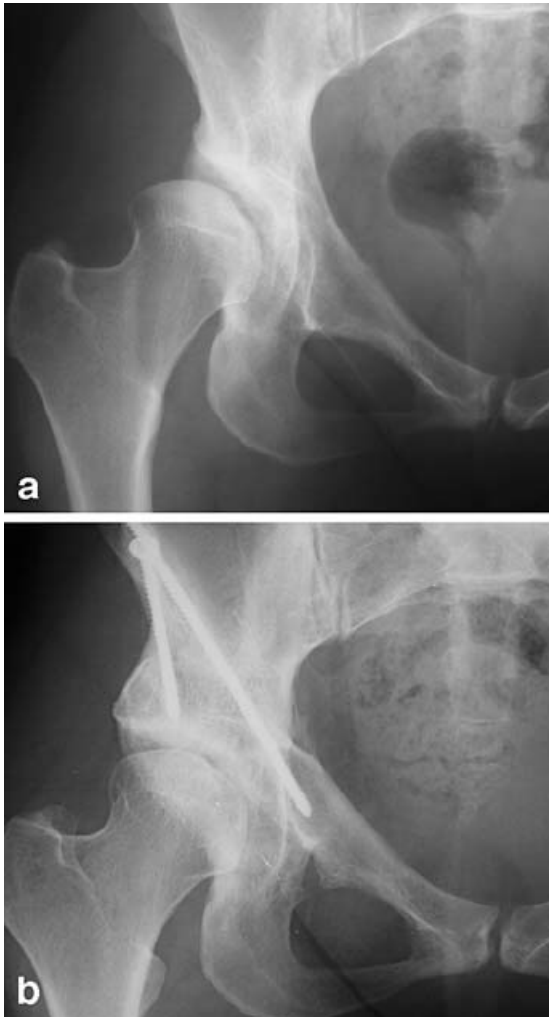

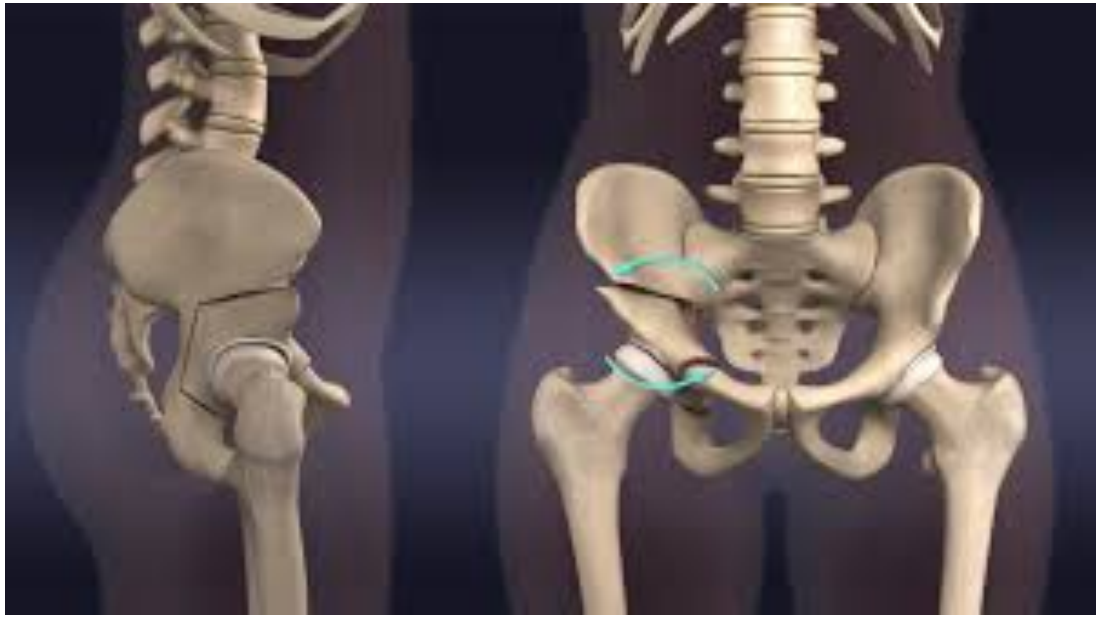

COXARTHROSIS : Traitement

FAI-surgery

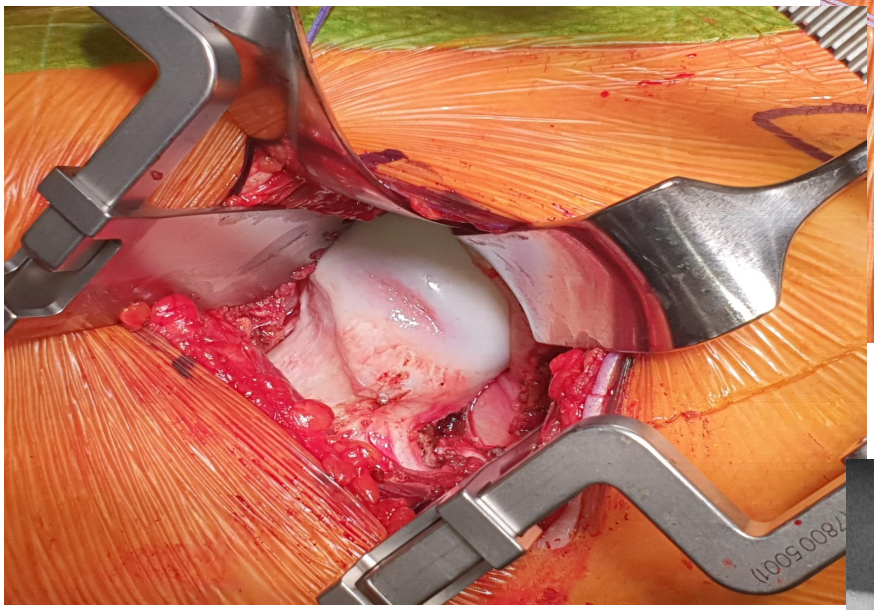

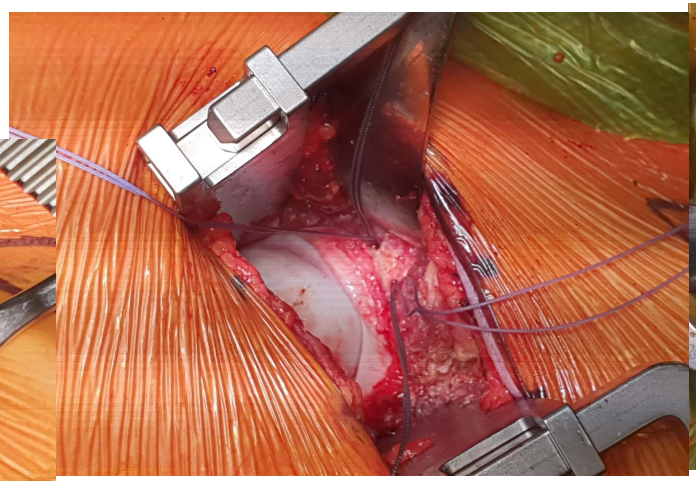

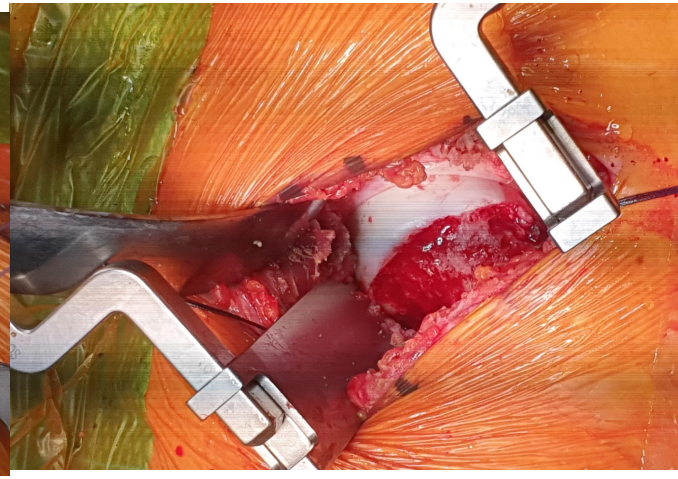

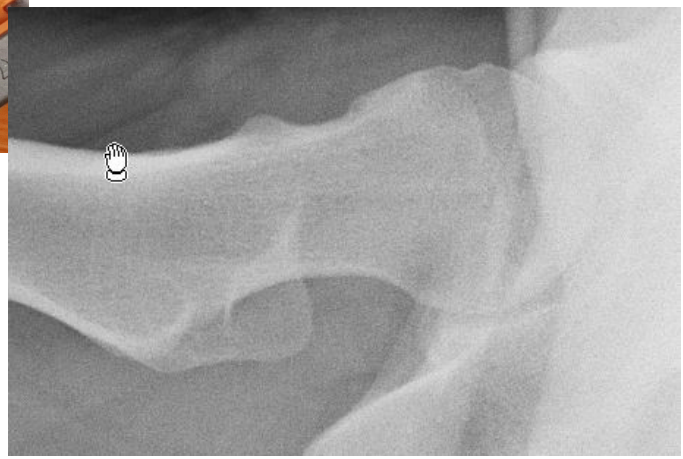

Therapeutic options

Total hip arthroplasty

THA

« The operation of the century: total hip replacement »

Learmonth et al. ***The Lancet***, volume 370, Issue 9597, Oct 2007

History

Wiles' acetabular cup and resurface of head of the femur, 1938

Smith-Petersen mould, 1938

Judet brothers' acrylic femur head-replacement, late 1940s

Moore intramedullary endoprosthesis, 1950s –

Charnley low-friction arthroplasty, 1958 –

Exeter total hip replacement, 1970 –

History

McMinn Birmingham resurfacing, 1991 –

History

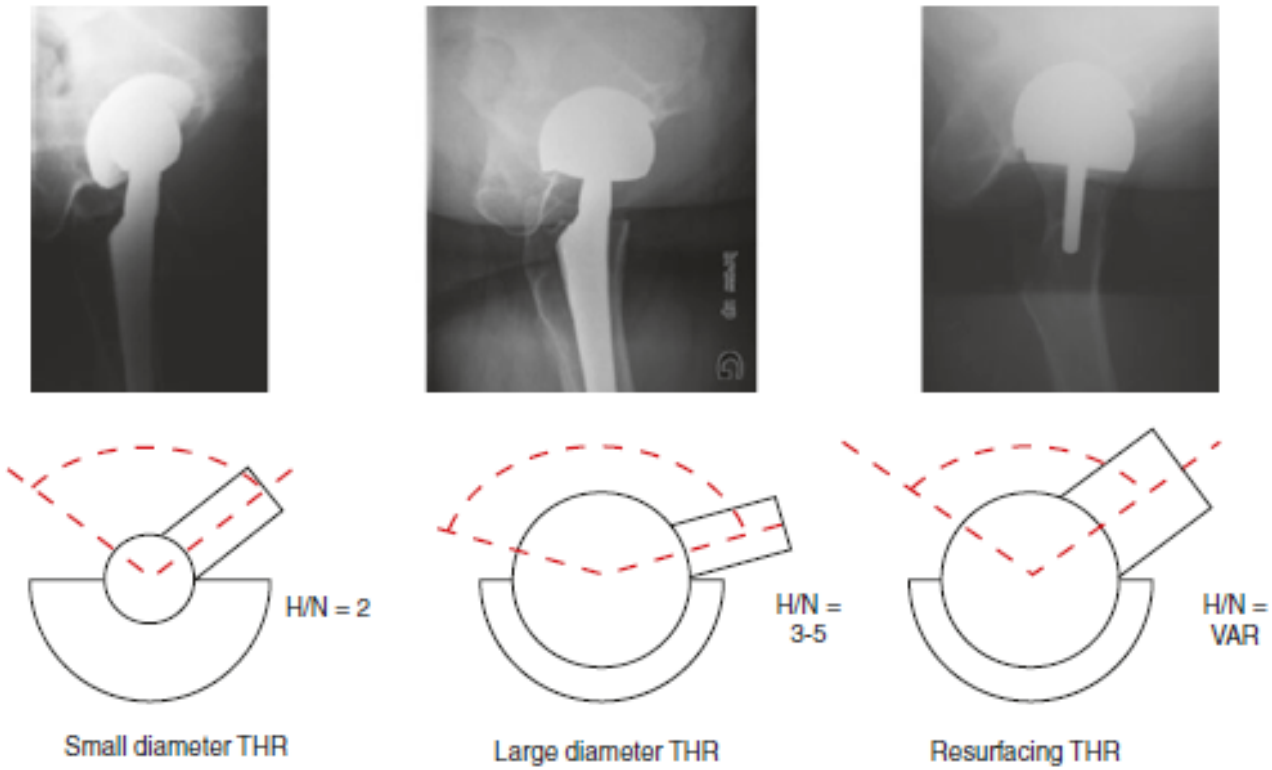
H/N = 2
Small diameter THR
H/N =
3-5
Large diameter THR
H/N =
VAR
Resurfacing THR

Modern THA

PTH Basic principles

Surgical approach

Fixation modes

Choice of implants depending on different conditions:

- the indications
- The age

Surgical approaches

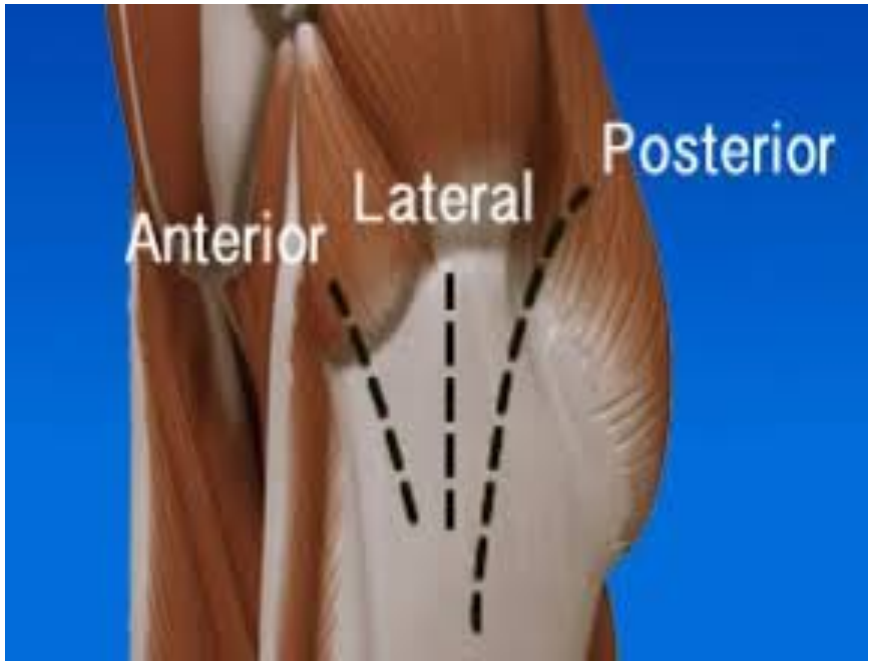

EXEMPLE D'ABORD TRANSGLUTEAL

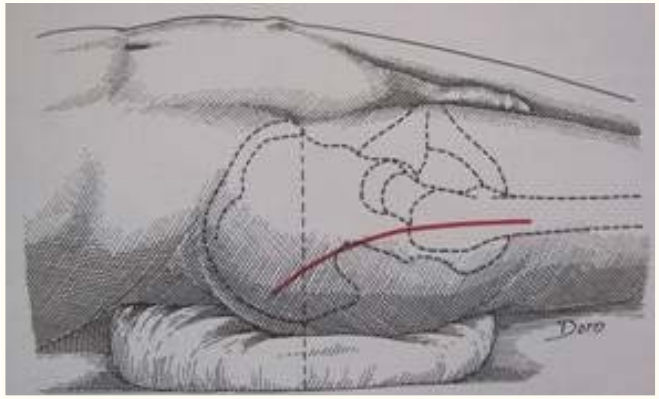

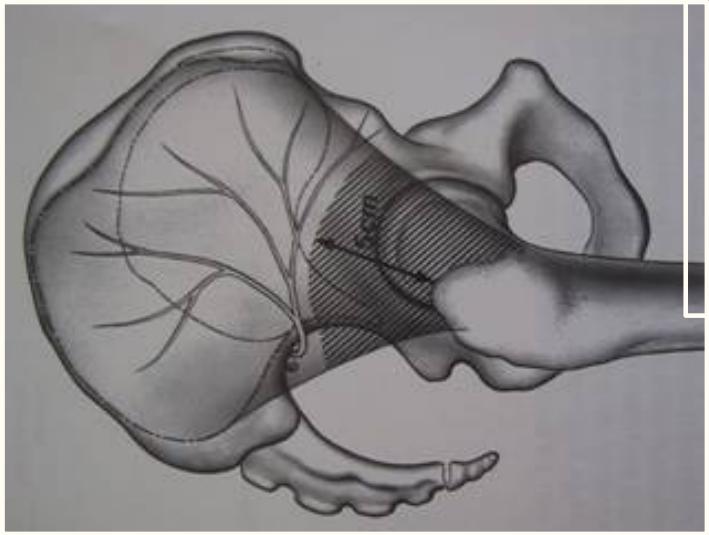

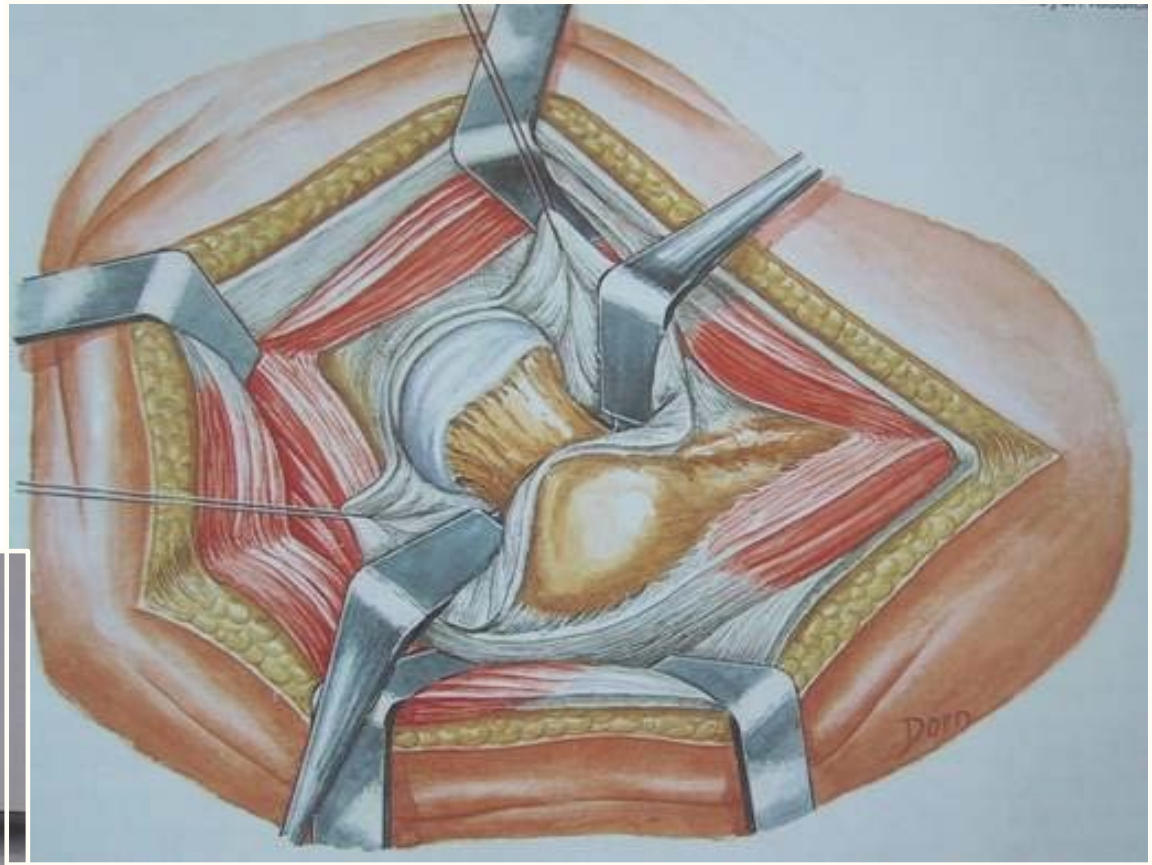

Installation en décubitus latéral

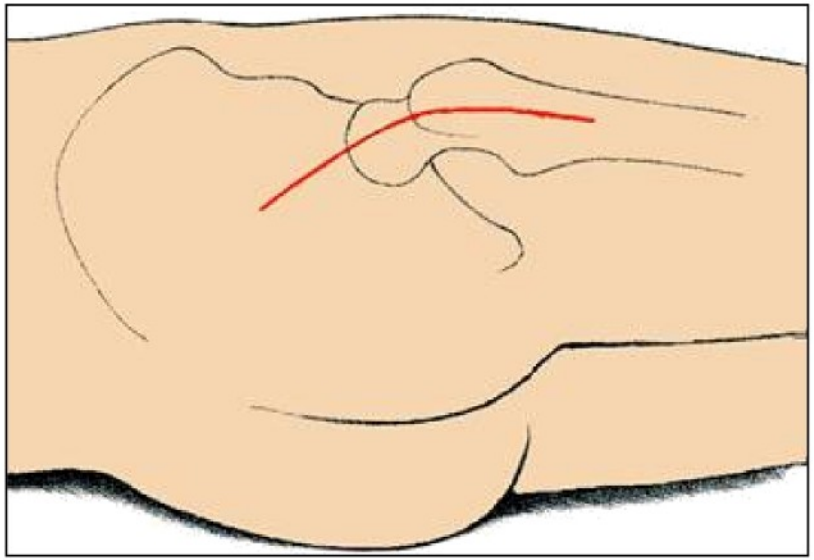

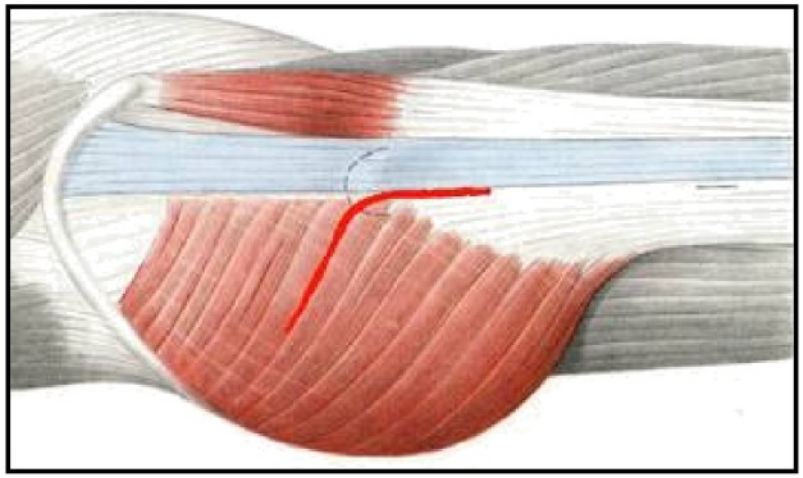

Posterior approach

Exposition de la hanche par voie postérieure

Ouvrir la capsule pour exposer la hanche

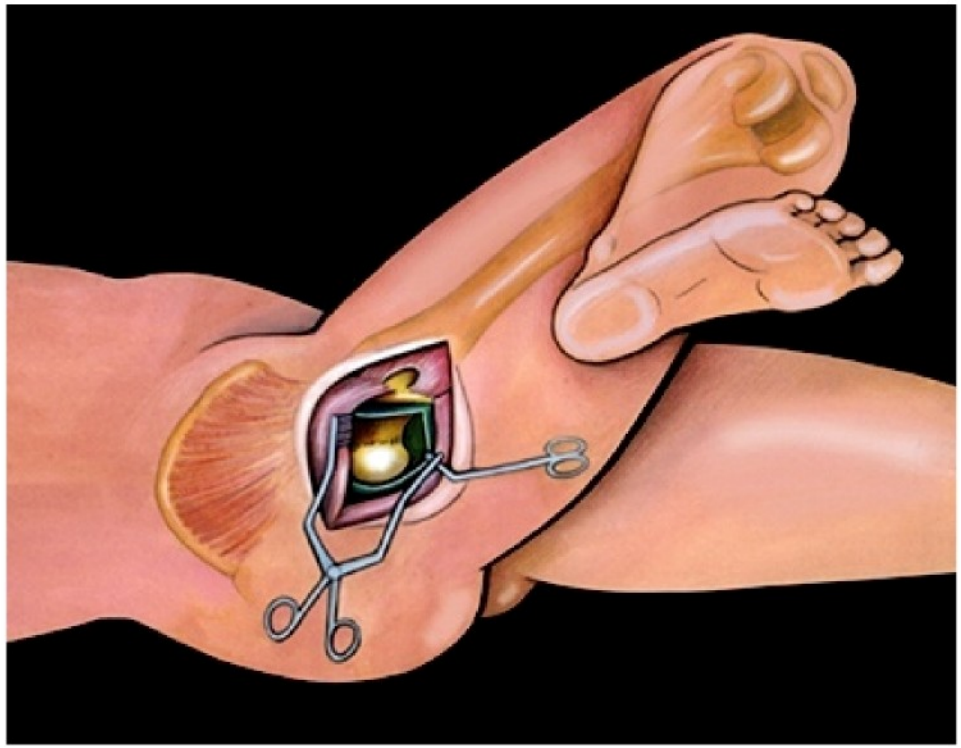

Luxation dela hanche en rotation interne

Section de la tête à la base du col

Préparation de la cavité fémorale et du cotyle

Direct anterior approach

- Pat in supine position

- with or without traction table

- true intermuscular plane

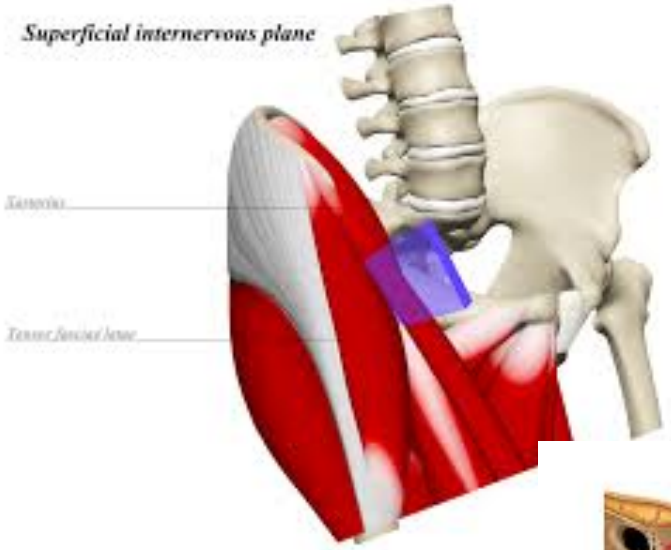

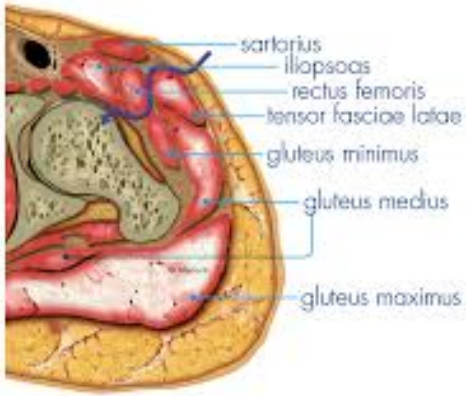

Choice of implants



Choice of implants

Choice of implants

Metal on Polyethylene

Metal on Metal

Ceramic on Ceramic

Double-mobility

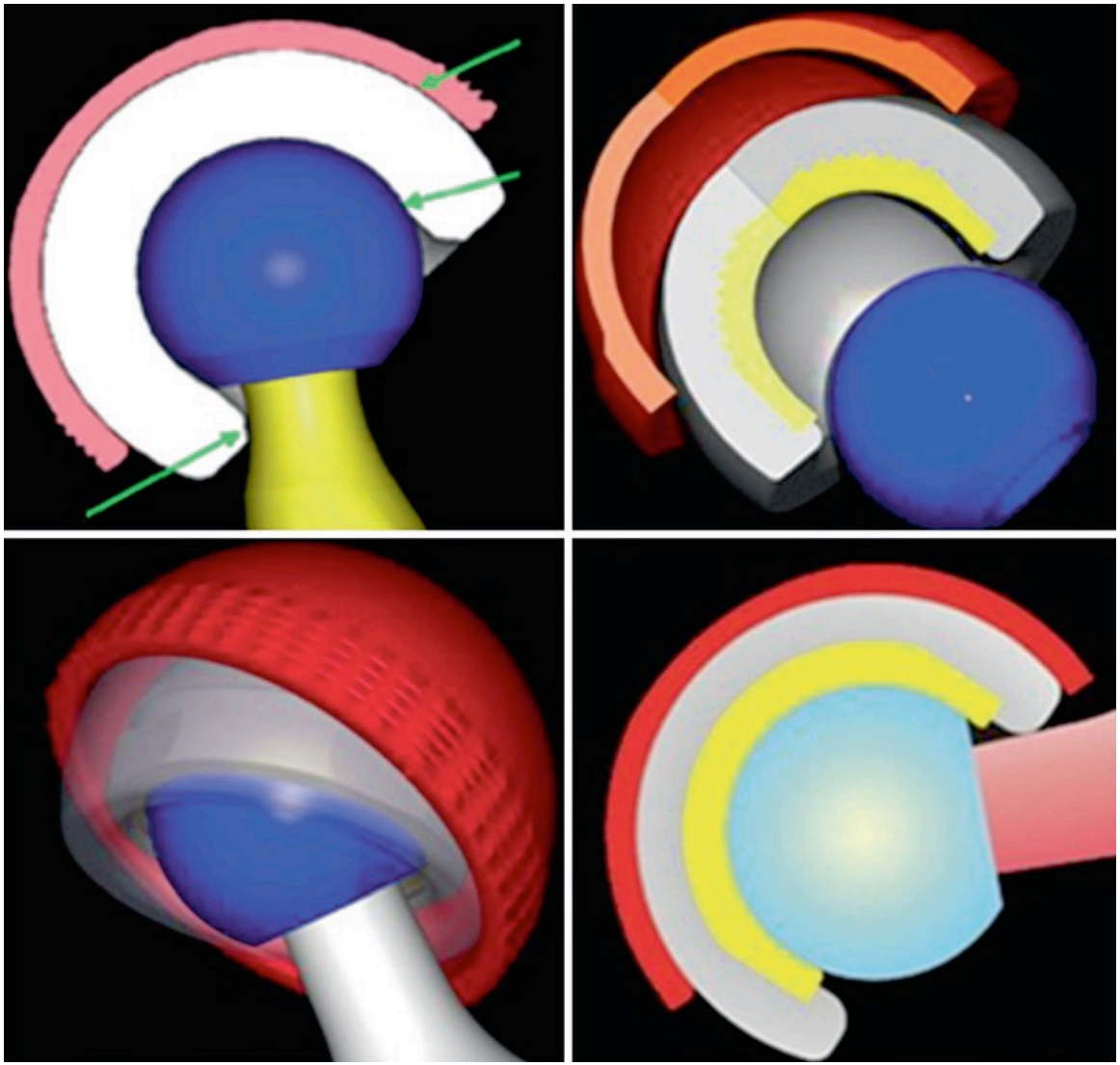

Preoperative planification

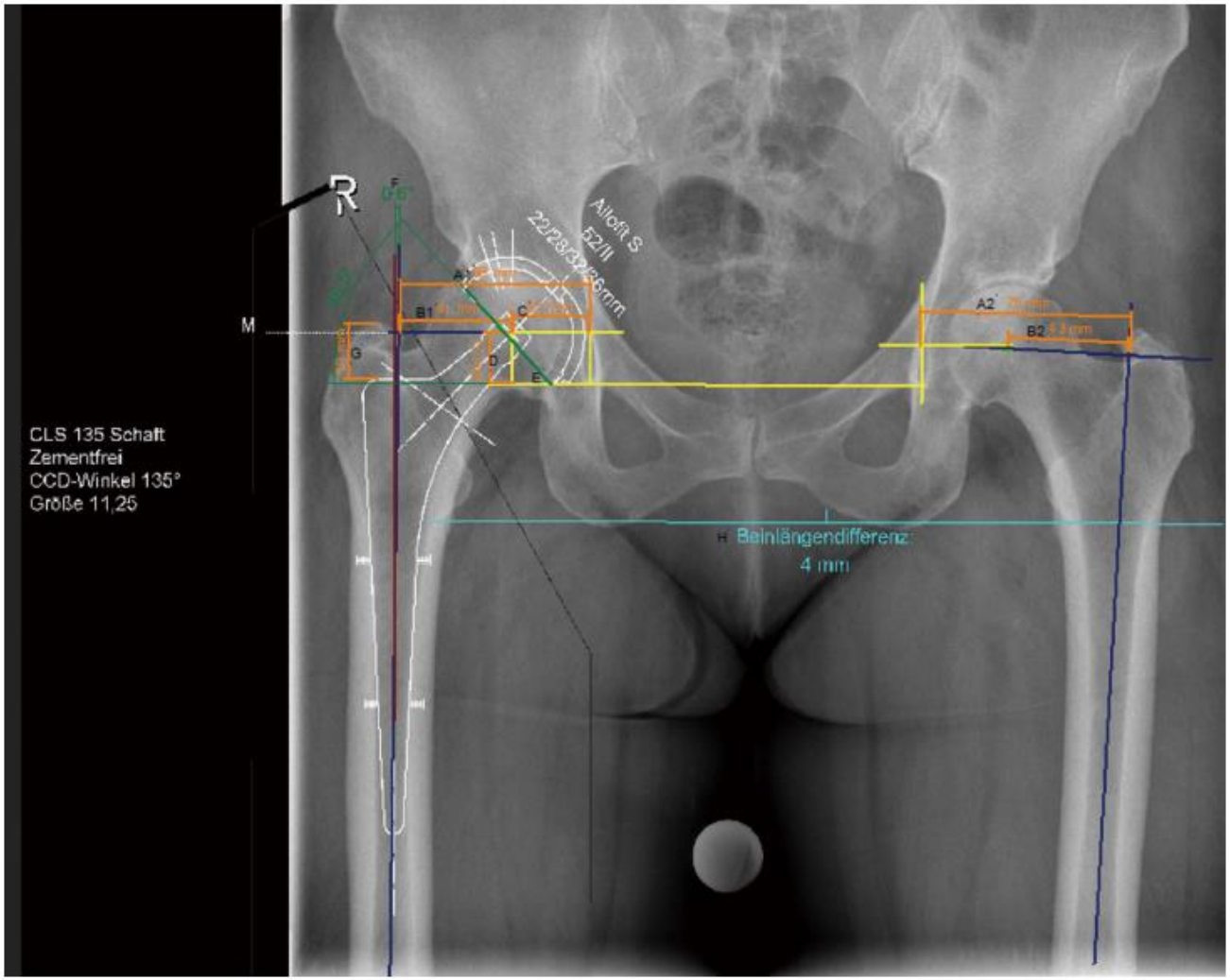

Preoperative planification

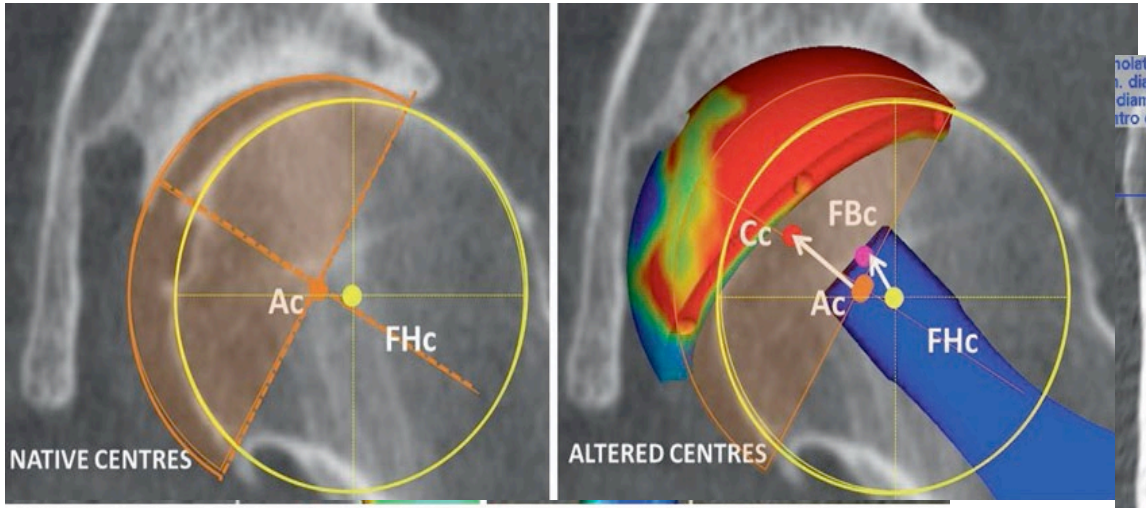

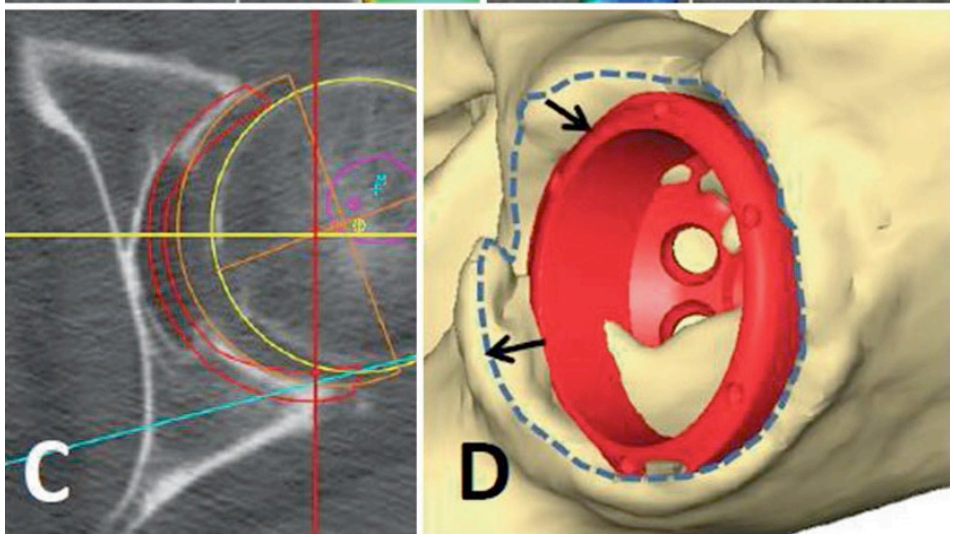

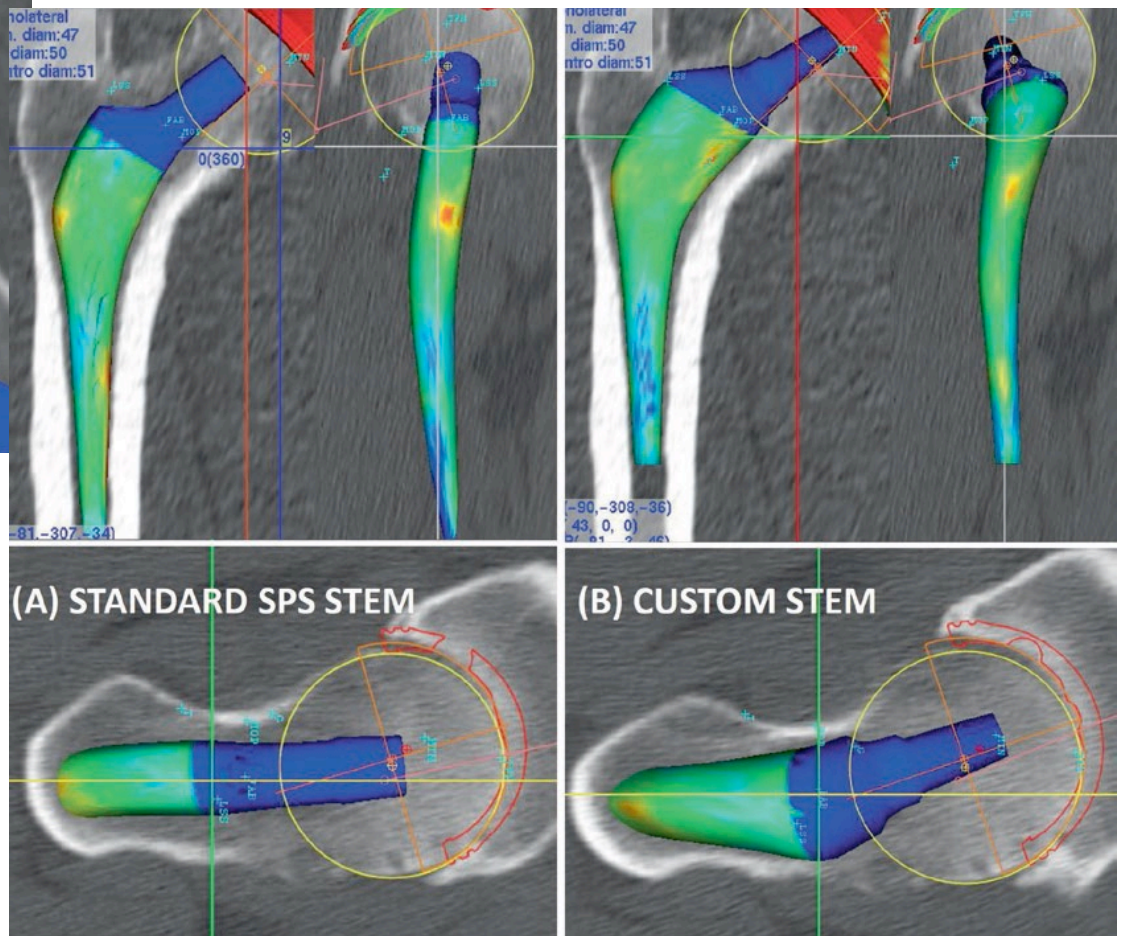

Cup Implantation

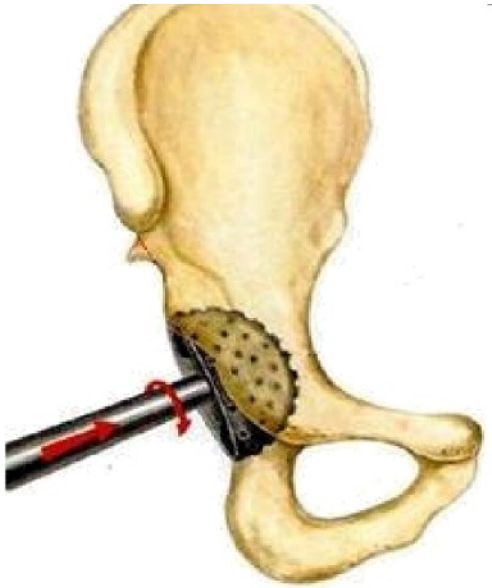

Reaming

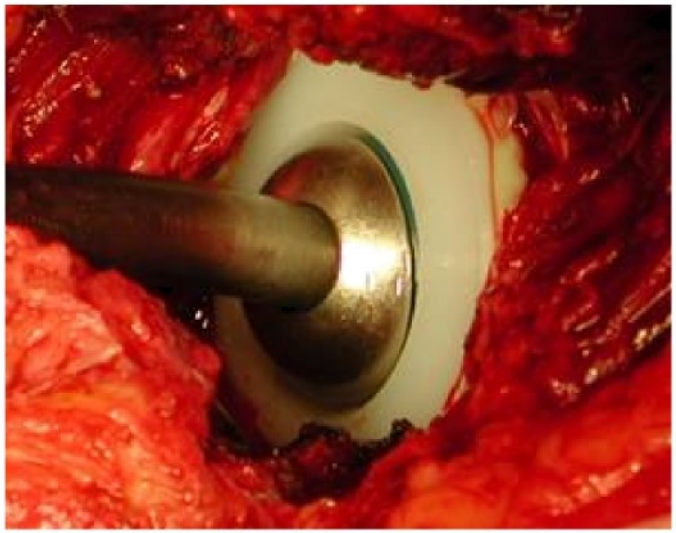

cement mantel

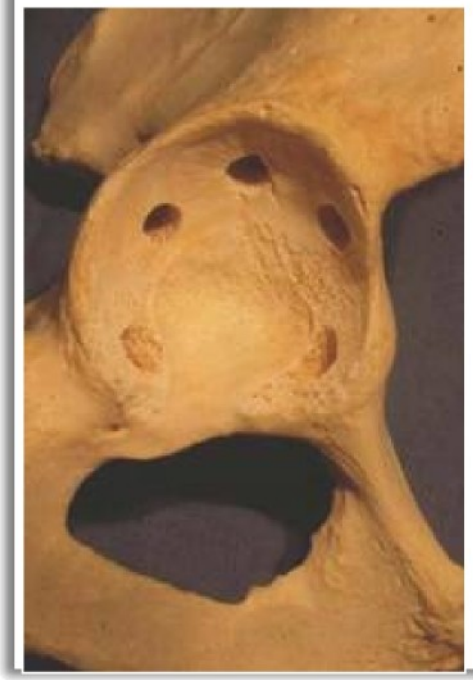

Acetabular preparation

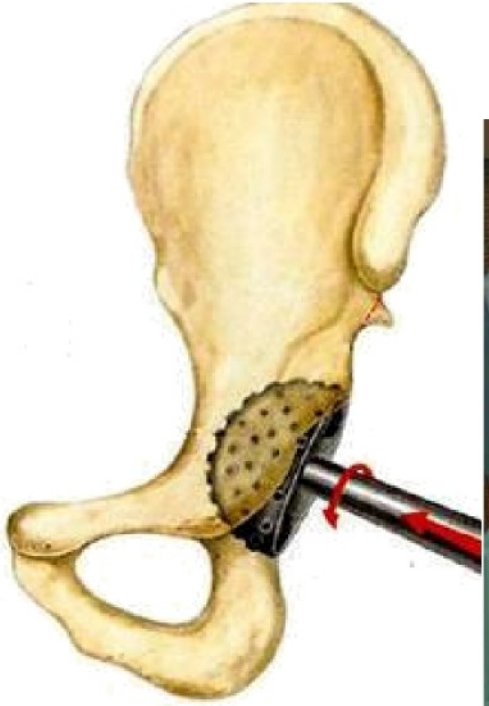

Cup implantation without cement

Implantation of the femoral stem

Preparation of the femoral cavity using tailored rasps

Press-fit impaction

Or ciment introduction

The prothetic head is impacted on the cone

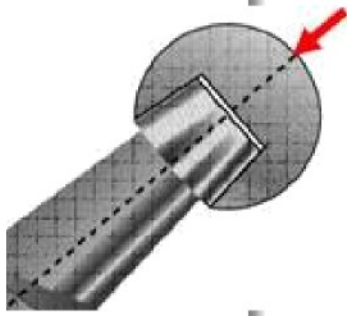

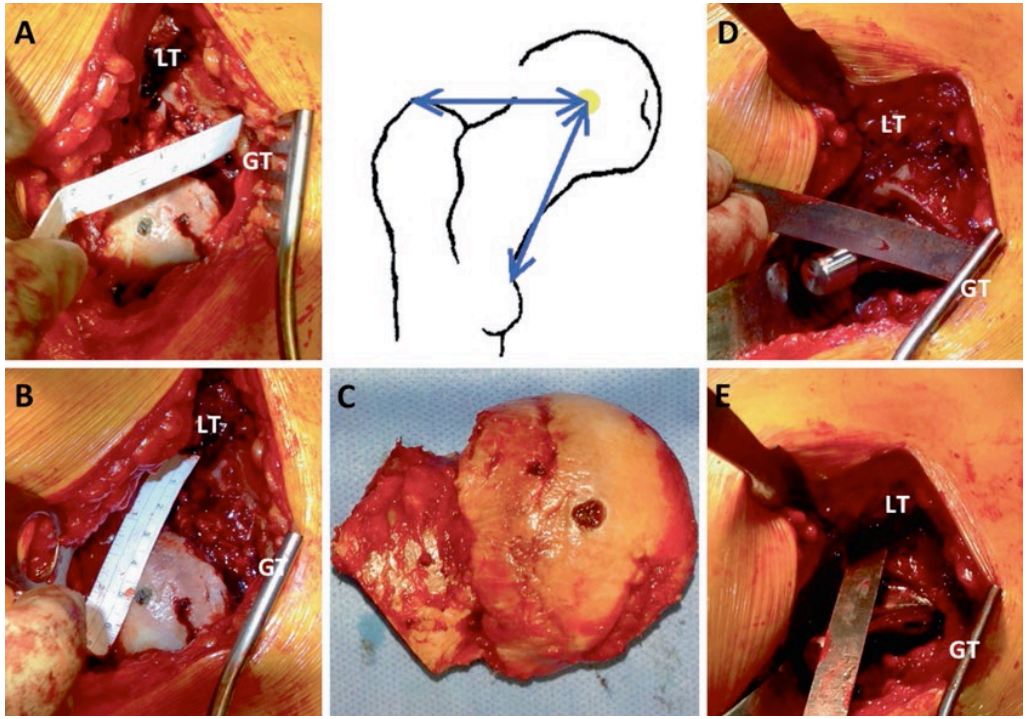
A
LT
GT
D
LT
GT
B
LT
GT
C
E
LT
GT

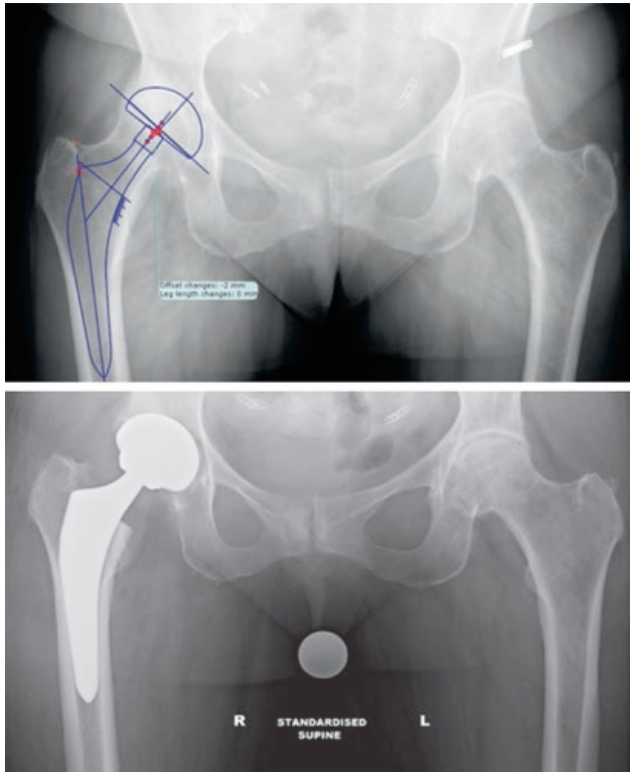
R
STANDARDISED
SUPINE
L

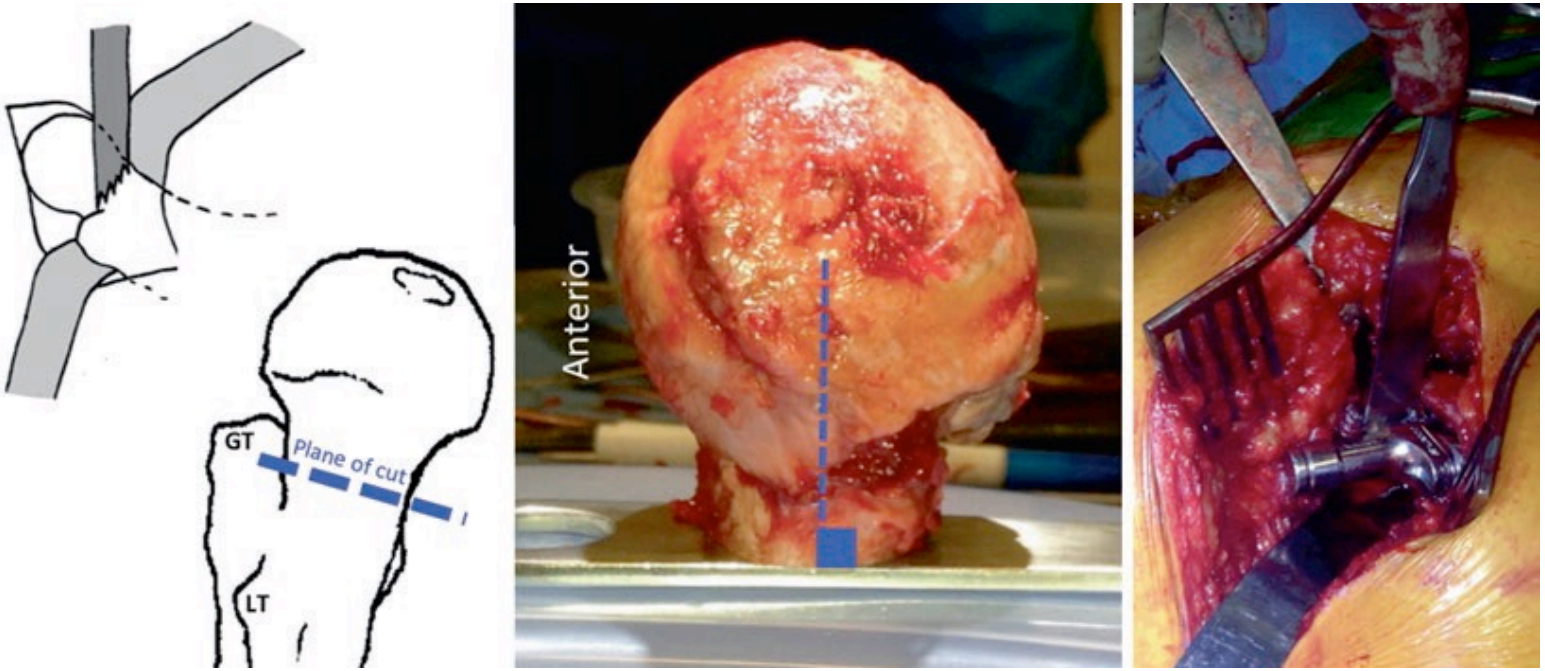
GT
Plane of cut
LT
Anterior

Postoperative x-ray

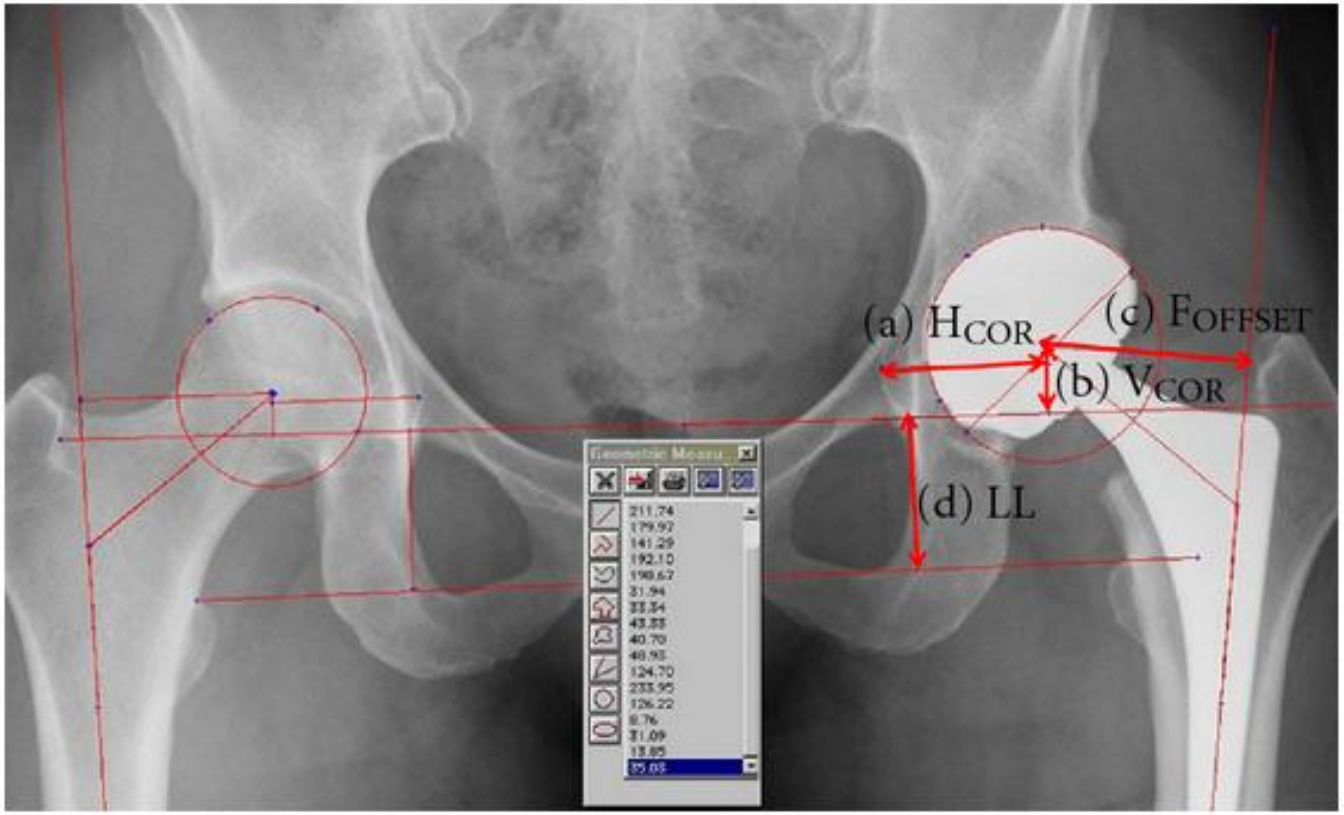

Osteoarthritis of the knee

GONARTHROSIS : classification

- Topographie: OA
  1, 2 ou 3 compartiments :
  - Medial OA
  - Lateral OA
  - Patellofem. OA

- +/- causal factors:
  — primary OA
  — Secondary OA

Osteoarthritis of the knee

- Knee OA is primarly provoced by mechanical factors:
  - — the deformation femoro-tibial
  - — modifications of the articular surface
  - — sequels of traumatisme
  - — post meniscectomie
  - — ligamentous ruptures(LCA)

Osteoarthritis of the knee

- deformation of the lower limb (morphotype)

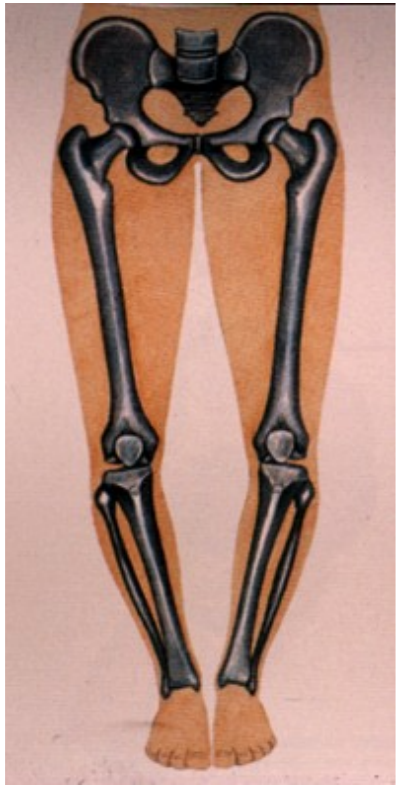

Medial osteoarthritis (varus knee)

- **The deviation of the axis leads to an accelerated wear**
- **The wear of the cartilage worsens the deformation**

Lateral osteoarthritis (valgus knee)

5-10%

The major deformation is mostly on the femur

KNEE OA

- Symptoms:
  - — pain
  - — functional deficit
  - — limping
  - — intraarticular effusion
  - — instability

Knee Osteoarthritis: diagnostic

Clinical exam:

- - morphotype (genu varum +++ : 90%)
- +/- déformation globale du genou
- Pain on paplation of the joint line
- Intraarticular effusion
- Popliteal cyst (Baker cyst)
- ROM limitation

Knee Osteoarthritis: diagnostic

RADIOLOGIE:

- x ray knee weight bearing a.p/lateral
- Schuss
- Skyline patella

Standing AP View PA Flexion View Lateral View Sunrise view

RADIOLOGIE

4 stages (Ahlbäck):

Stage 1 :

narrowing<50%

Stage 2 :

narrowing >50%

Stage 3 :

Attrition < 5mm

Stage 4 :

attrition >10mm

Pangonometrie:

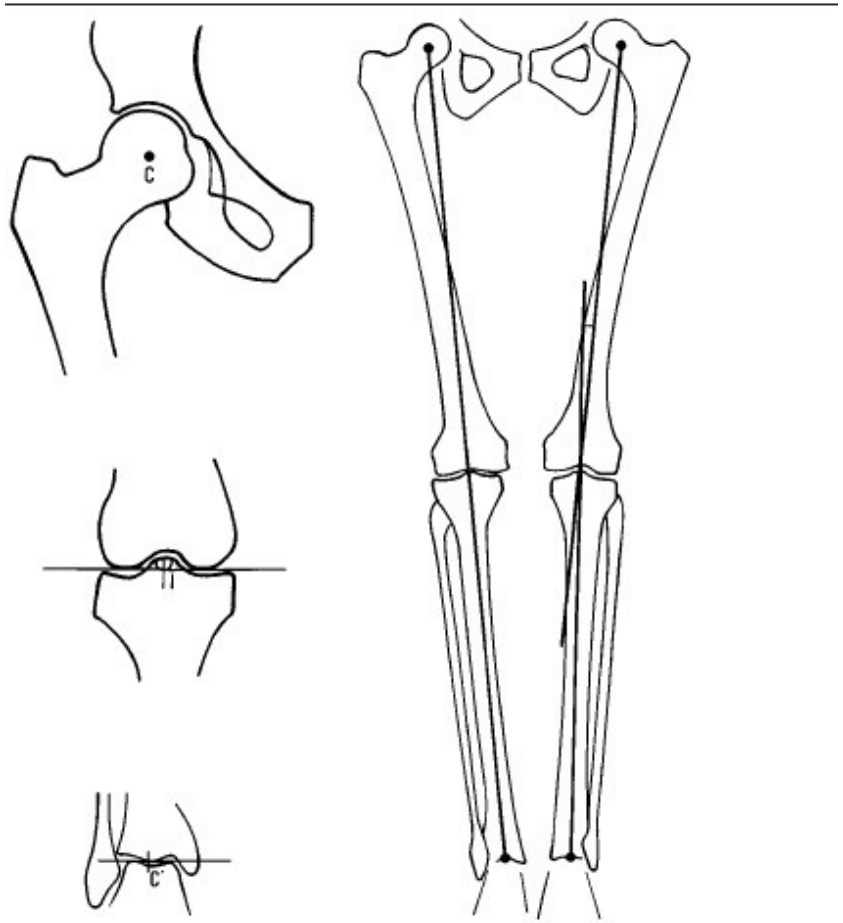

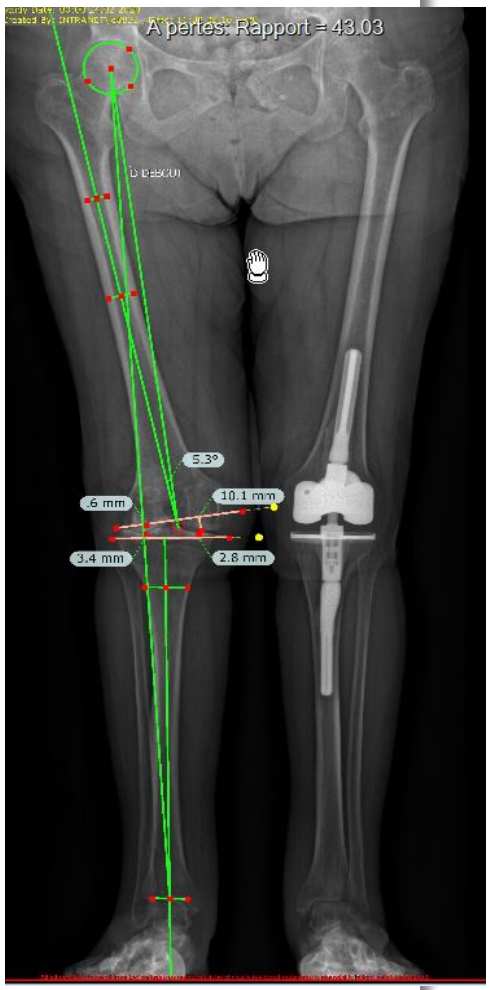

- Measurement of the axial deviation
- Surgical correction

Treatment

The NEW ENGLAND JOURNAL of MEDICINE

ORIGINAL ARTICLE

Arthroscopic Partial Meniscectomy versus Sham Surgery for a Degenerative Meniscal Tear

Raine Sihvonen, M.D., Mika Paavola, M.D., Ph.D., Antti Malmivaara, M.D., Ph.D., Ari Itälä, M.D., Ph.D., Antti Joukainen, M.D., Ph.D., Heikki Nurmi, M.D., Juha Kalske, M.D., and Teppo L.N. Järvinen, M.D., Ph.D., for the Finnish Degenerative Meniscal Lesion Study (FIDELITY) Group

- Treatment of early medial varus OA
  - Valgisation osteotomy
    High tibial open wedge osteotomy

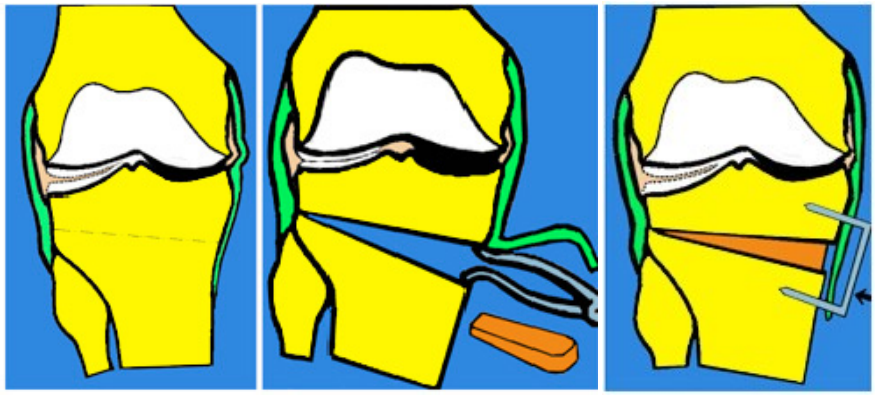

- Treatment of early medial varus OA
  - Valgisation osteotomy
    High tibial closing wedge osteotomy

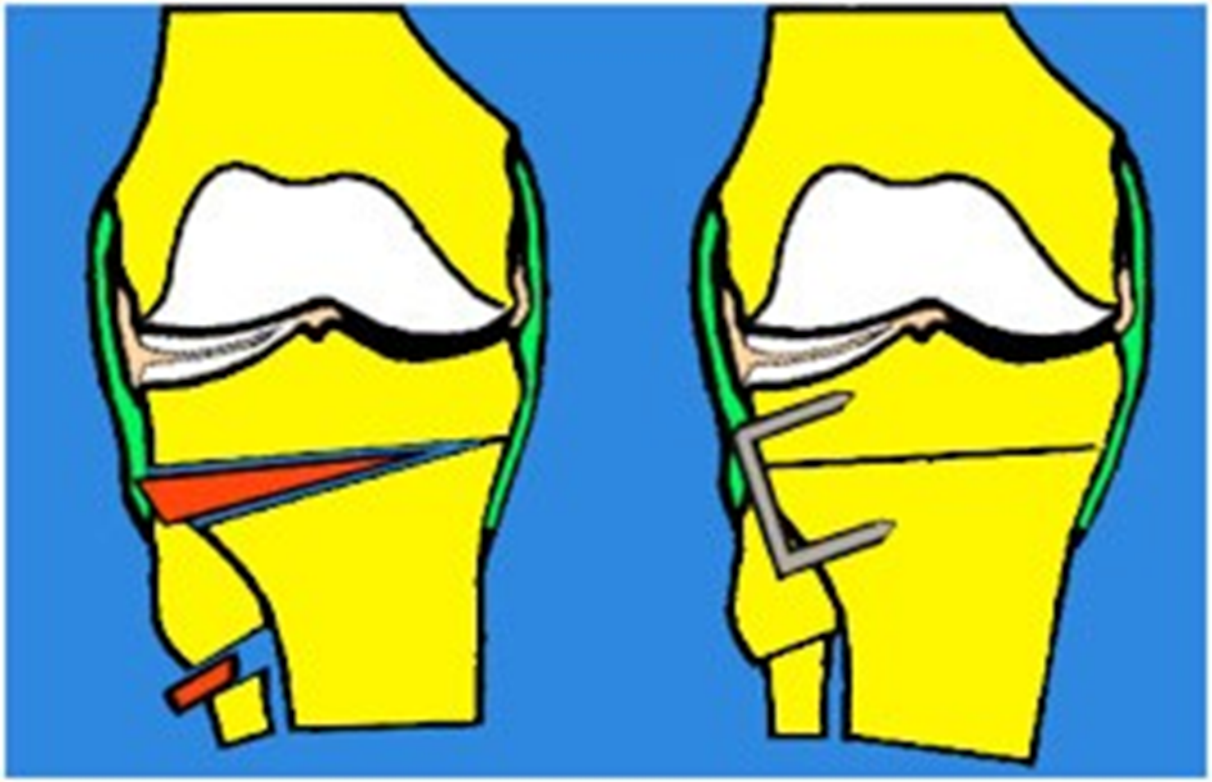

TREATMENT

- Treatment of early lateral valgus OA
  - Varisation osteotomy
    High tibial closing wedge osteotomy

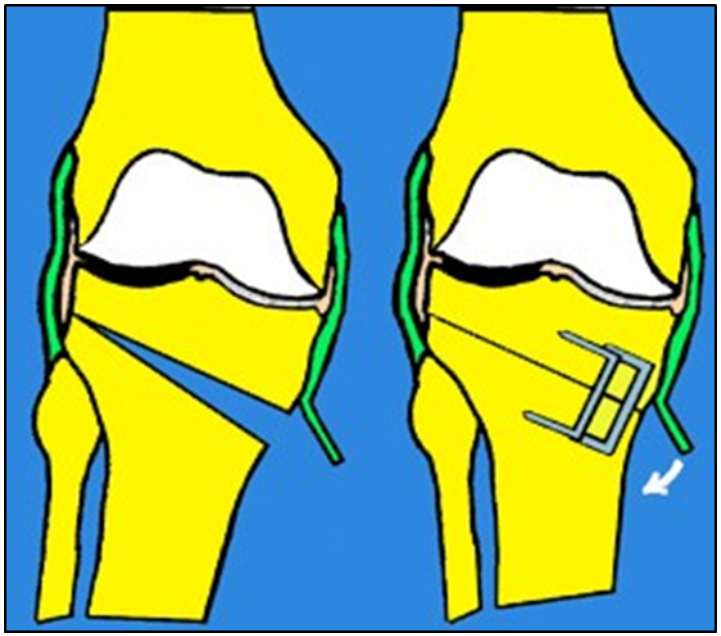

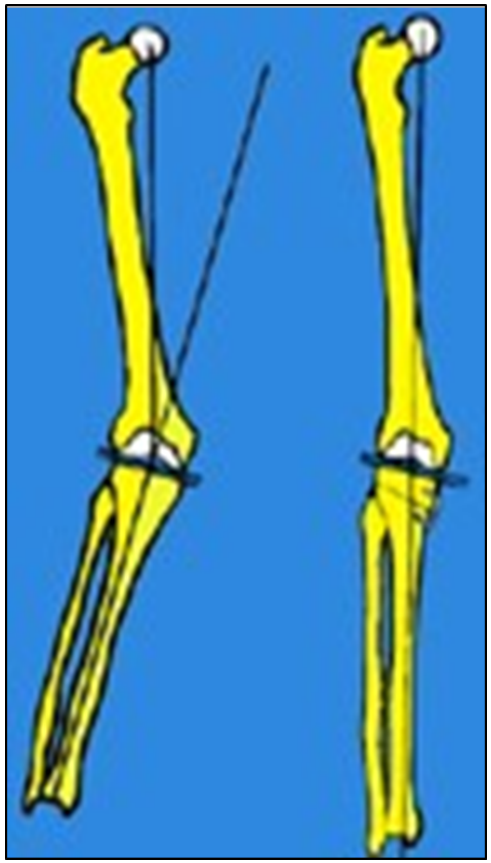

TREATMENT

- Treatment of early lateral valgus OA
  - Varisation osteotomy
    High tibial closing wedge osteotomy

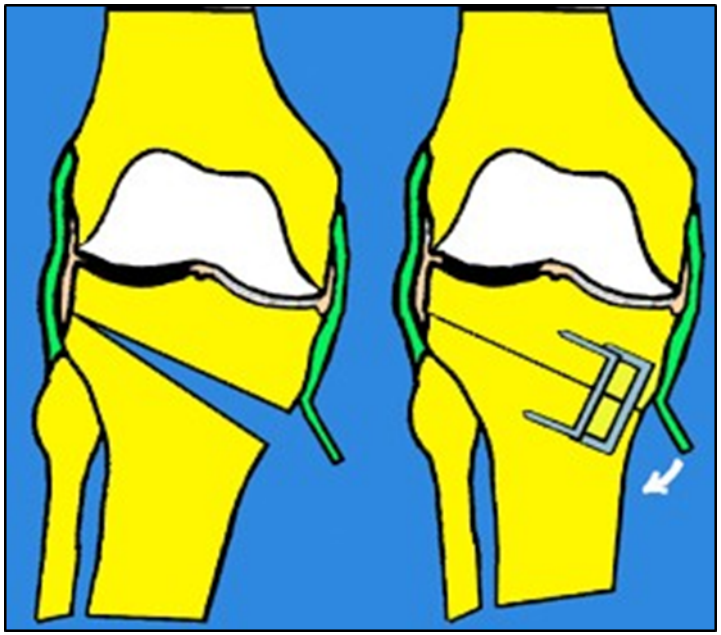

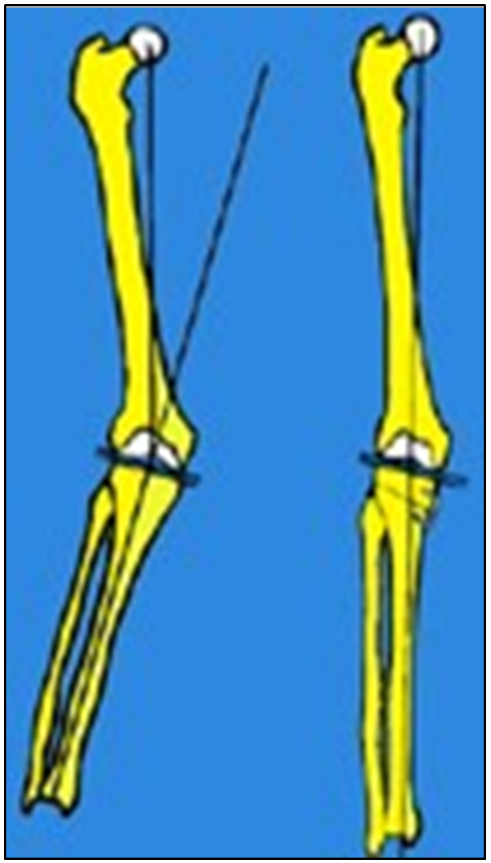

TREATMENT

- Treatment of early lateral valgus OA
  - Varisation osteotomy
    Distal femoral closing wedge osteotomy

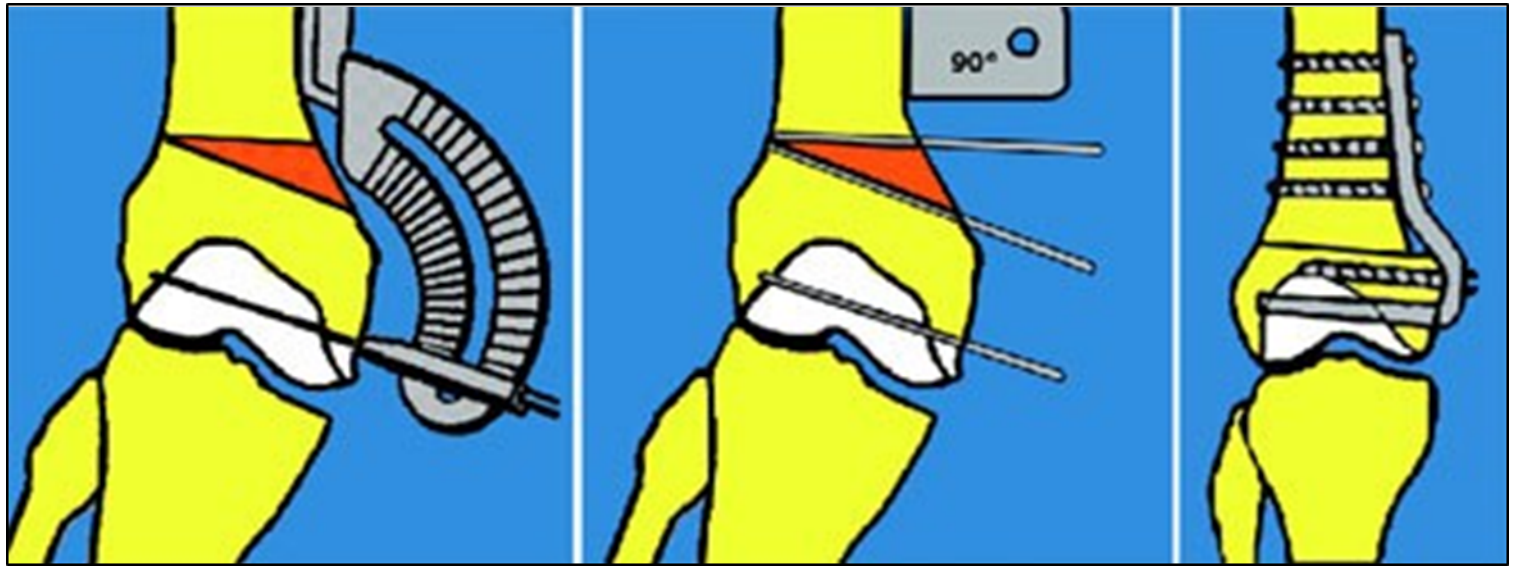

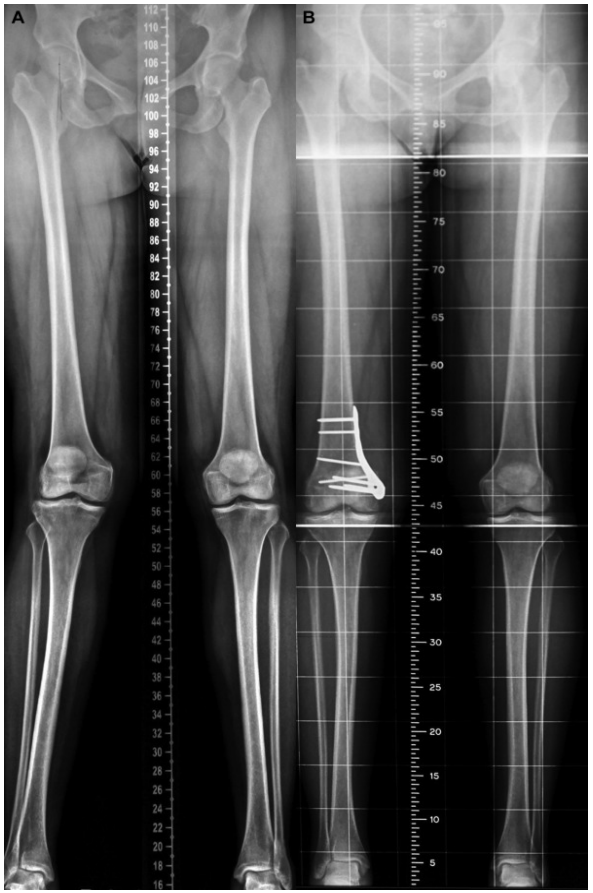

TREATMENT

- Treatment of advanced isolated OA
  - Unicompartmental arthroplasty (medial, lateral or patellofemoral)

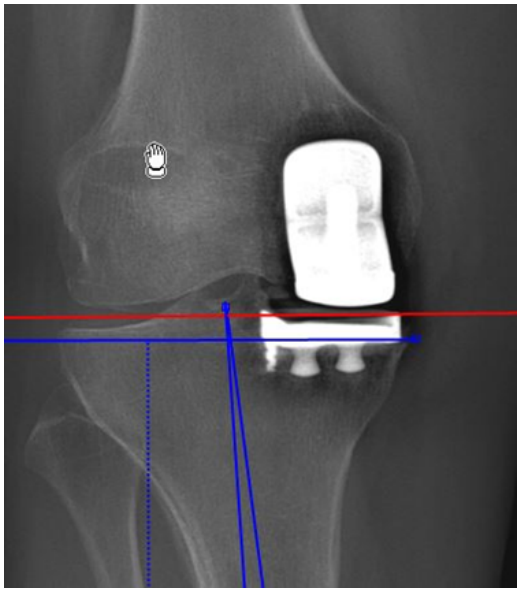


TREATMENT

- Treatment of advanced OA
  - Total knee arthroplasty (tricompartimental resurfacing)

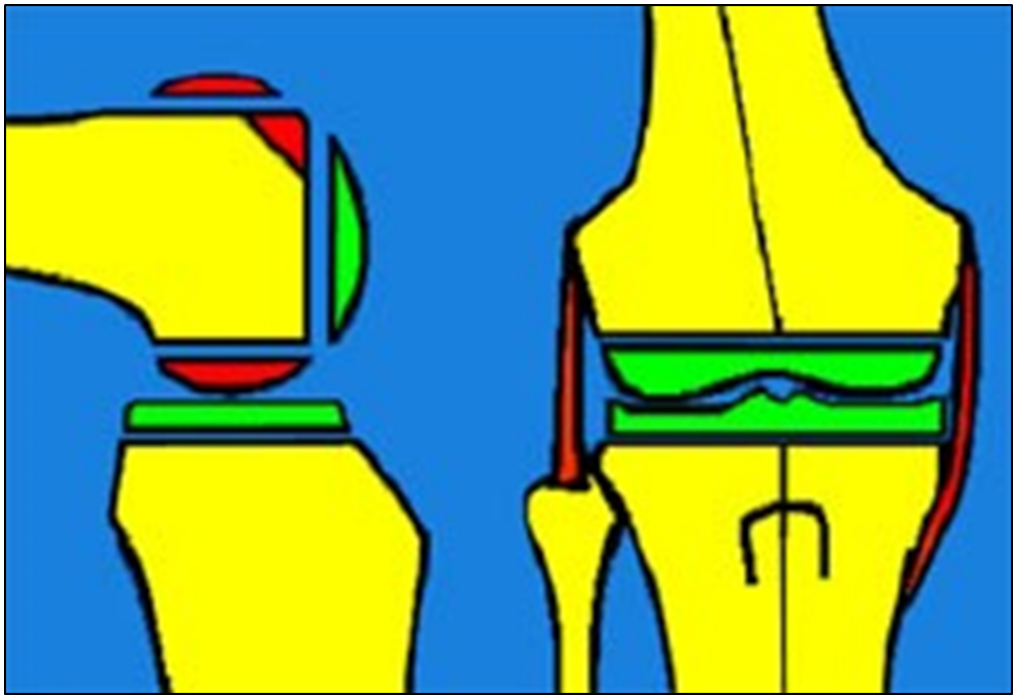

TREATMENT

- Surgical technique

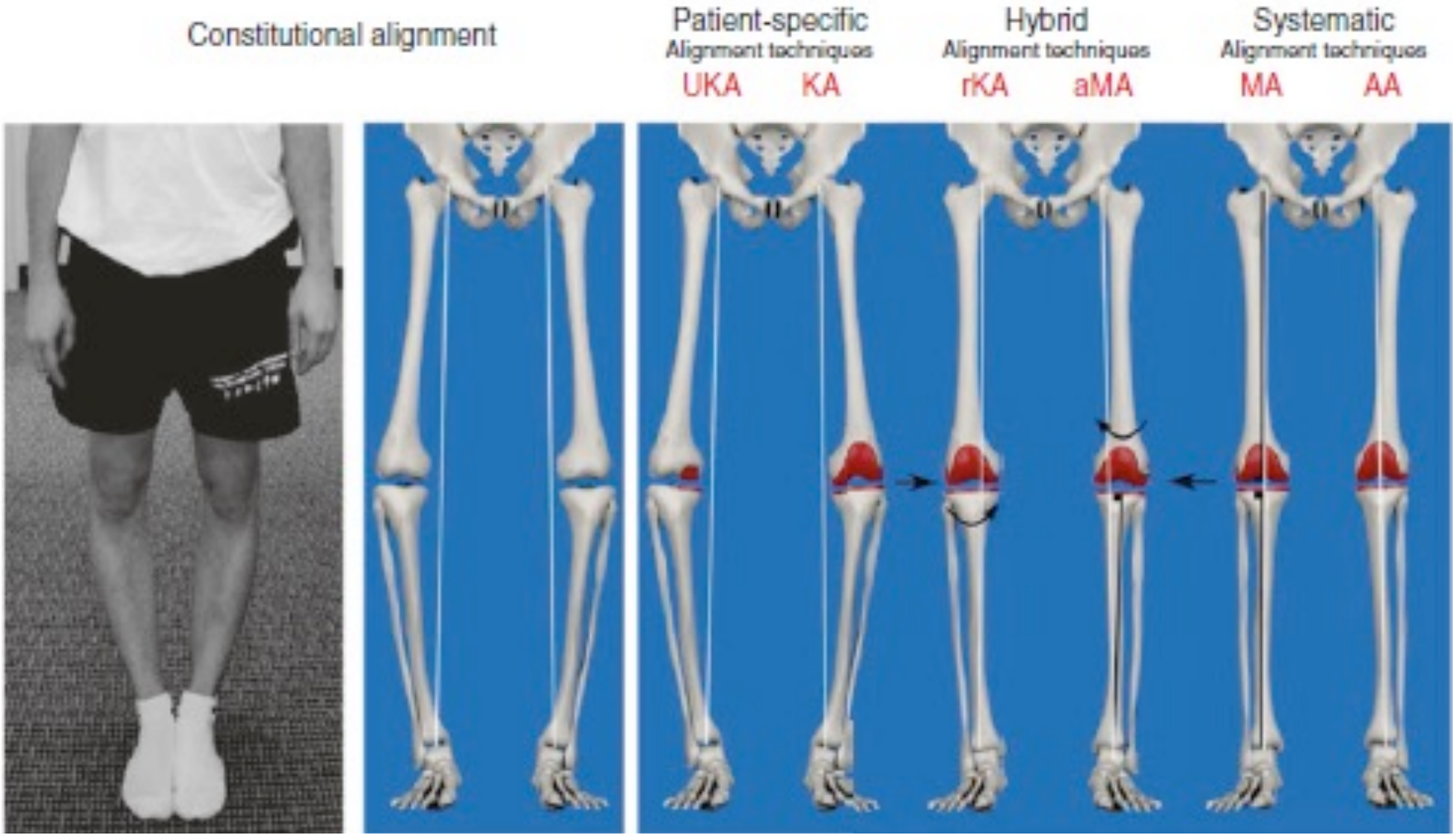

- Mechanical aligment

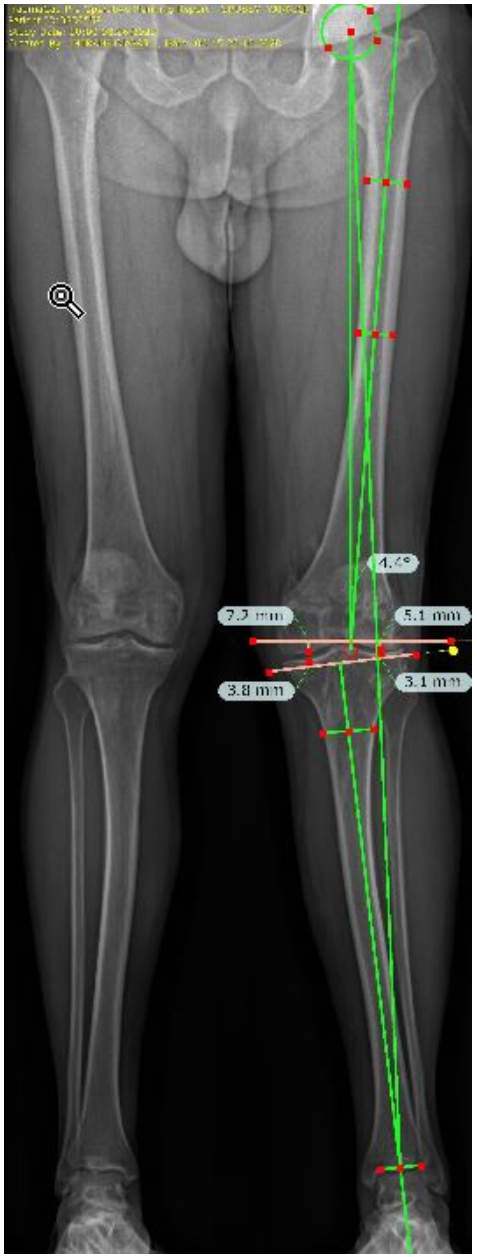

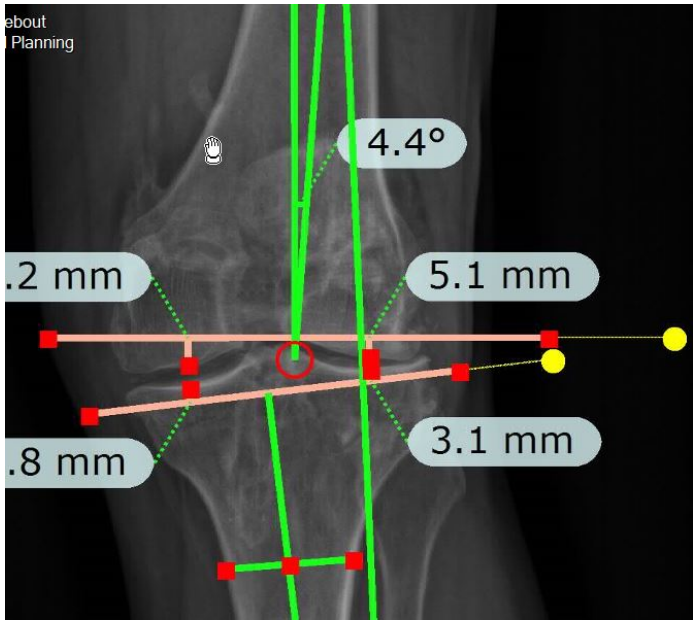

Tibial resection

- Tibial cut

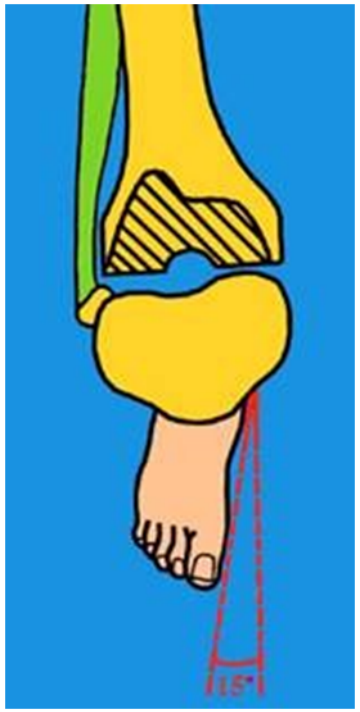

Tibial resection

- Tibial cut

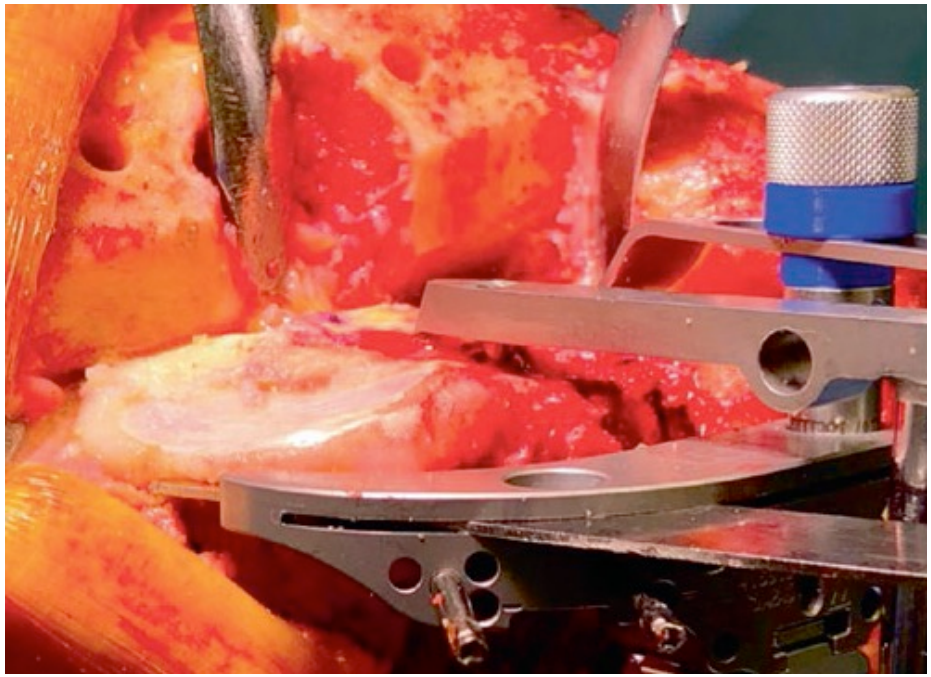

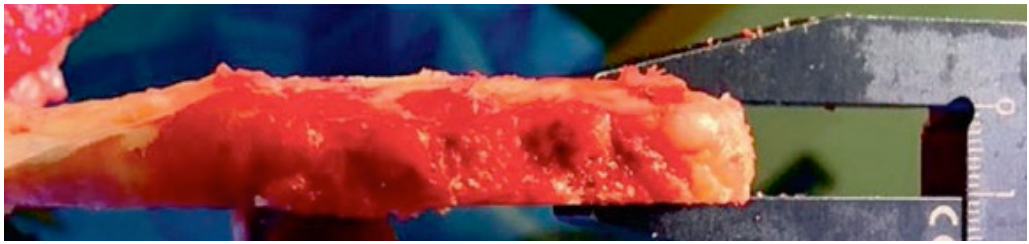

Femoral resection

- Distal femoral cut

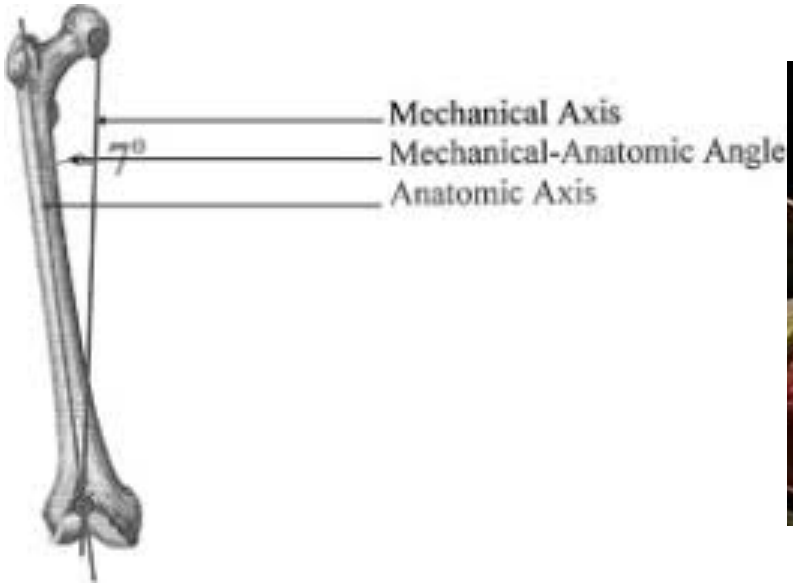



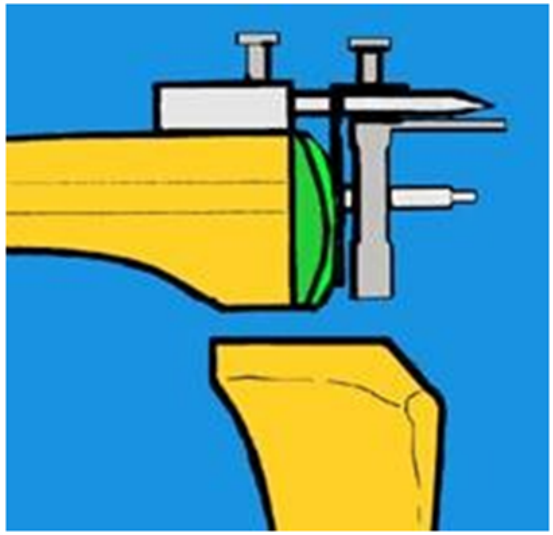

Ligament balancing

- Balance in flexion and extension

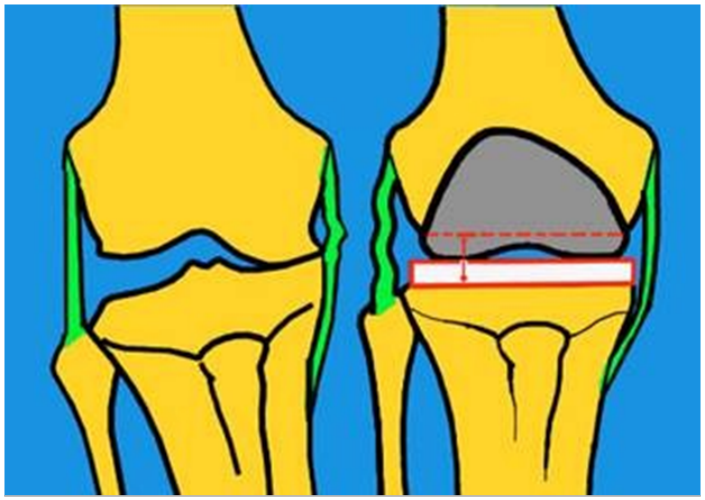

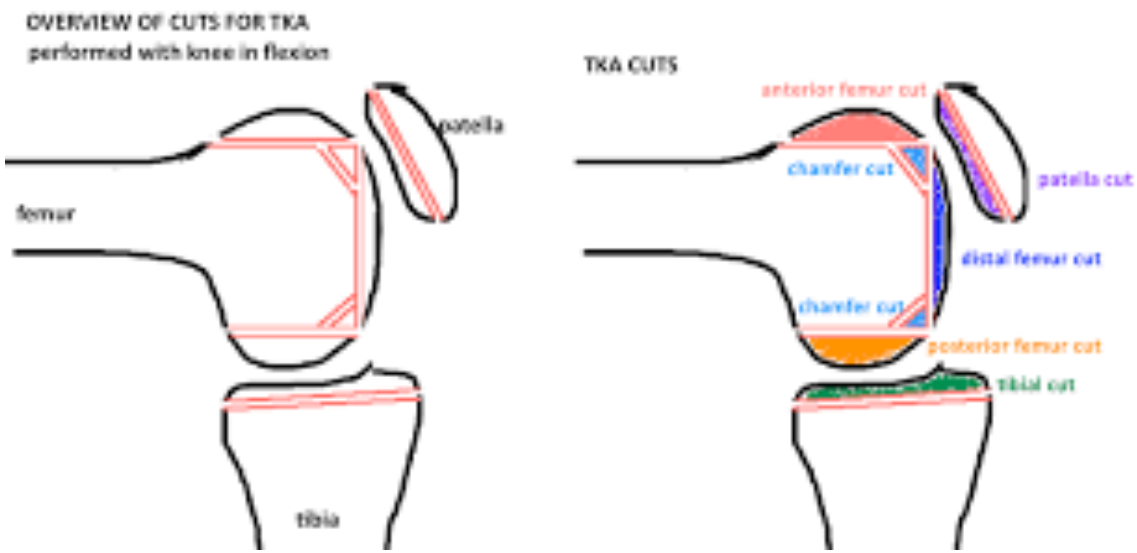

Ligament balancing

- Balance in flexion and extension

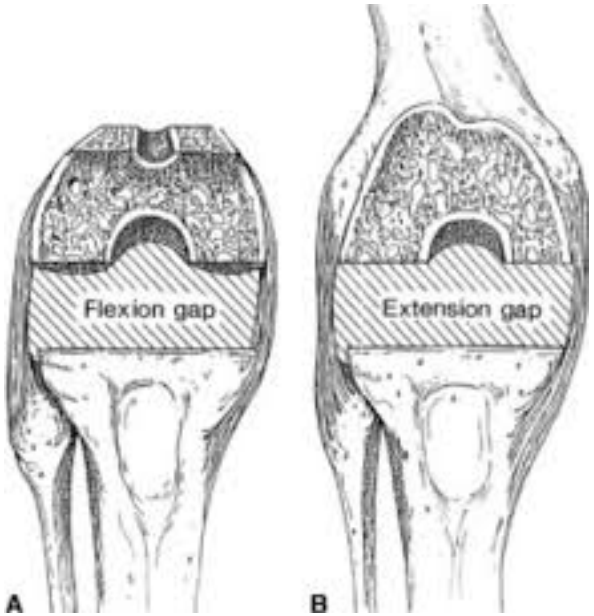

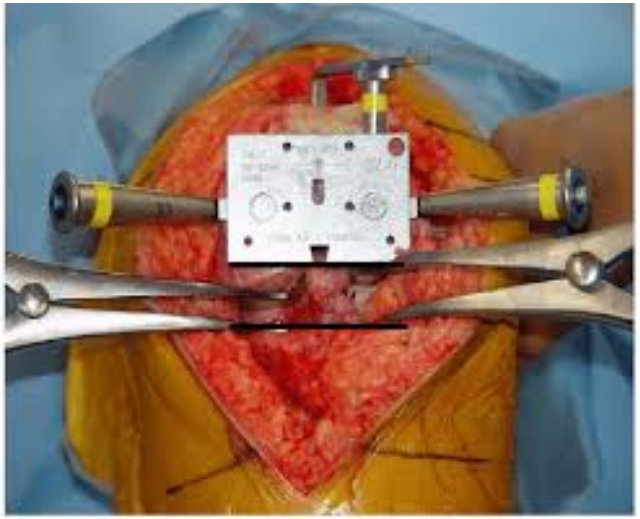

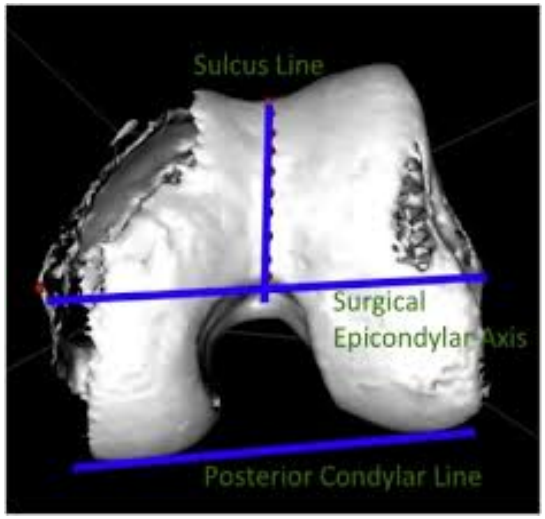

Navigation

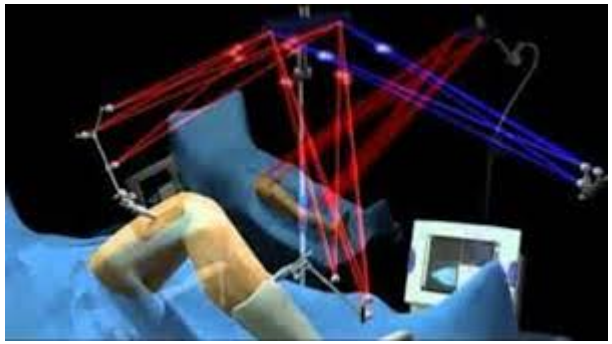


a
b
c
d
e

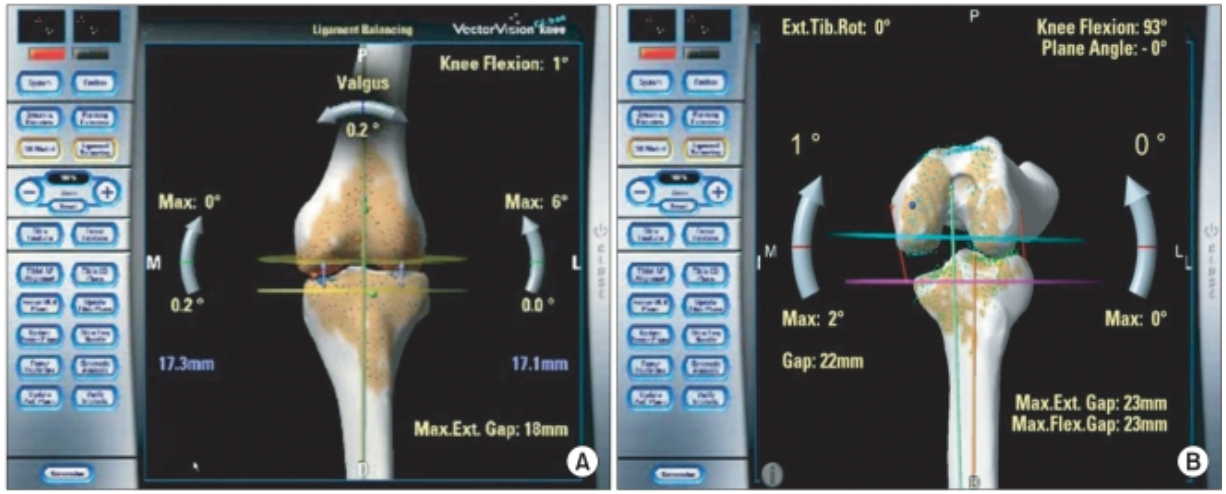
Ligament Balancing
VectorVision knee
Knee Flexion: 1°
Valgus
0.2 °
Max: 0°
Max: 6°
M
L
0.2 °
0.0 °
17.3mm
17.1mm
Max.Ext. Gap: 18mm
A
Ext.Tib.Rot: 0°
P
Knee Flexion: 93°
Plane Angle: - 0°
1 °
0 °
M
L
Max: 2°
Max: 0°
Gap: 22mm
Max.Ext. Gap: 23mm
Max.Flex.Gap: 23mm
B

Robotic assisted surgery

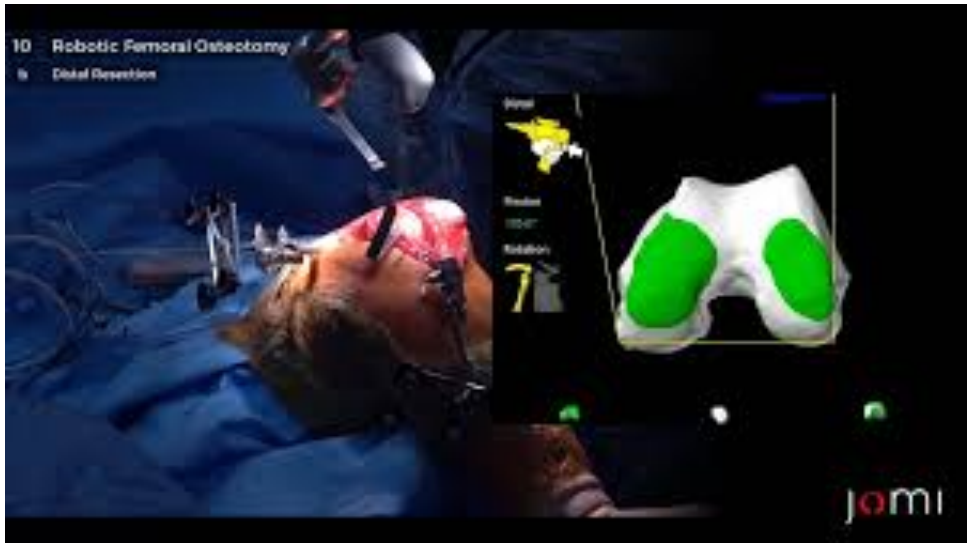

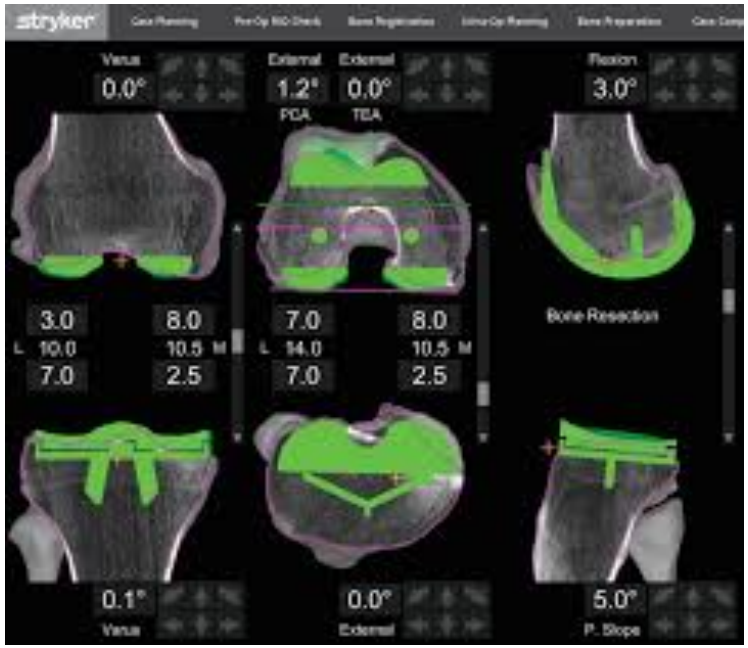

Merci

canton de vaud

CHUV