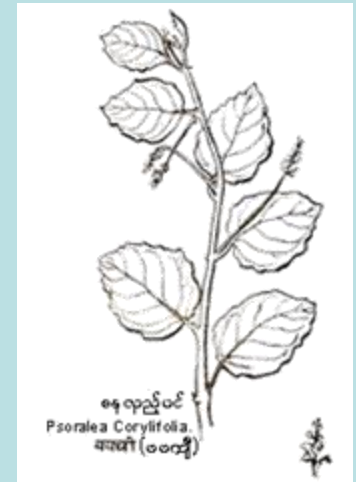

2. History of Photomedicine and biomedical optics: The antique

Man has recognized the relation between light and health for about 3000 years

Ancient medical literature: treatment of de-pigmented skin areas (vitiligo) by application of plant seeds (psoralea) followed by the exposure to sunlight



1500 BCE
India



500-200 BCE
Buddhism literature



1000 CE
China



1500 BCE
Egypt
(Ebers Papyrus)



BCE | CE




Vitiligo



Later and turn of the 18th century

1775

J. Priestley discovers oxygen



1806

Ph. Bozzini invents a device to "make visible the inner cavities of the body"
=> first endoscope

Early and middle of the 19th century


1841

Johann Joseph Scherer removes iron from blood with concentrated sulfuric acid => Hematoporphyrin



1842 : Louis Pasteur and Paul Bert report phototoxicity in cells and germs

Becquerel and Draper: spectral extent of UV radiation



1852 : Georges G. Stokes introduces the term "Fluorescence", interprets the light-emitting phenomenon, and formulates the "Stokes law"

1859 : Kirchoff and Bunsen invent the spectroscope

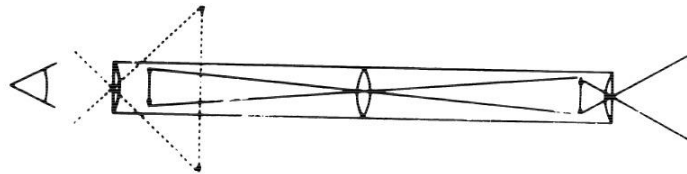
Late 19th century (2)

1876/77

Jablochkow and Brush invent the first useful carbon electrode arc lamp



1877 : Nitze develops the first cystoscope based on a telescopic lens system




1879 : Th. A. Edison invents the incandescent lamp

The Beginning of modern Photomedicine

1893-1903

N.R. Finsen develops the phototherapy



Copyright (C) 2006 W*O GmbH

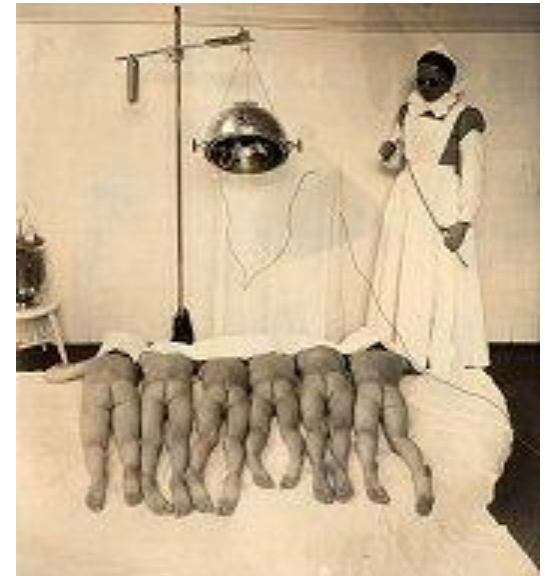
(Finsen lamp)

1893

Treatment of smallpox (variole) with red light

1895

Treatment of lupus vulgaris (skin tuberculosis) with artificial UV light from the "Finsen lamp"



(Phototherapy for tuberculosis, Finsen Institute, ~1900)




Niels Rysberg Finsen

(*15.12.1860, +24.9.1904)

"Pioneer of Phototherapy"

1893 Finsen discovered that UV light aggravated smallpox (la variole), but that red light improved healing

1895 treatment of lupus vulgaris (dermal tuberculosis) first with sunlight and then with artificial UV light (Finsen light)



1903 Nobel Prize *"in recognition of his contribution to the treatment of diseases, especially lupus vulgaris, with concentrated light radiation, whereby he has opened a new avenue for medical science"*

Paul Ehrlich (*14.3.1854, + 20.8.1915)



Paul Ehrlich "Father" of the chemotherapy
1897 Idea of cell-targeting therapy:



*"If we picture an organism as infected by a certain species of bacterium, it will...be easy to effect a cure if substance have been discovered which have a specific affinity for these bacteria and act...on these alone...while they possess no affinity for the normal constituents of the body...such substances would then be...**magic bullets**"*

1908 Nobel Prize in Physiology and Medicine for his scientific work in immunology

Discovery of Photosensitization


1900

J. Prime (french neurologist) used eosin orally in the treatment of epilepsy and showed that this induced dermatitis in sun-exposed areas of skin

[Prime J. (1900) "Les accidents toxiques par l'eosinate de sodium." Jouve and Boyer, Paris]

1900

Oscar Raab discovers the biological photosensitisation using chemical substance followed by exposure to light (acridine red on bacteria)




Discovery of Photosensitiation, cont.

1901 Cooper-Hewitt produce the first commercially available mercury vapor lamp

1903 H. von Tappeiner and A. Jesionek treat skin cancers with eosin dye followed by exposure of the lesions to sunlight

1904 H. von Tappeiner introduces the term "photodynamic action" and conclude that the presence of oxygen is a necessary requirement to obtain photosensitization



[H. von Tappeiner, A. Jodlbauer, "Über Wirkung der photodynamischen (fluoreszierenden) Stoffe auf Protozoen und Enzyme", Dtsch Arch Klin Med 80, 427 (1904)]

Early 20th century

1906

Coolidge invents the Tungsten lamp

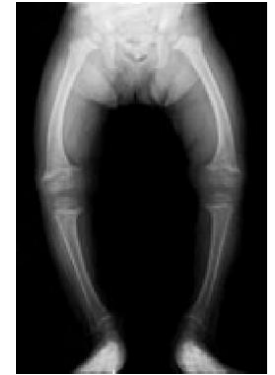1911/1913

Otto Heimstaedt and Heinrich Lehmann develop the first fluorescence microscope

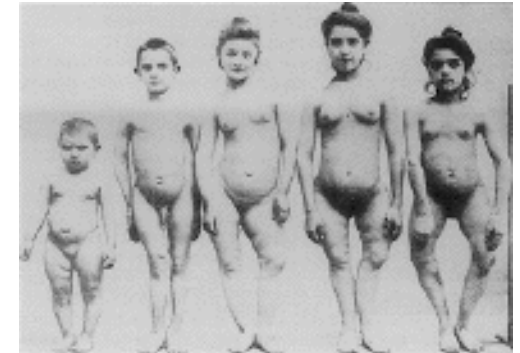
Rickets (Rachitisme)

1919 K. Huldschinsky first cures children of rickets using artificially-produced UV light following the observations of T. Palm (1848–1928)

Rickets (osteomalacia): a frequent childhood disease in developing countries
 Origin: vitamin D (calcium) deficiency
 Symptoms: bone pain and tenderness; skeletal deformity
 (bowed legs, cranial, spinal, and pelvic deformities)

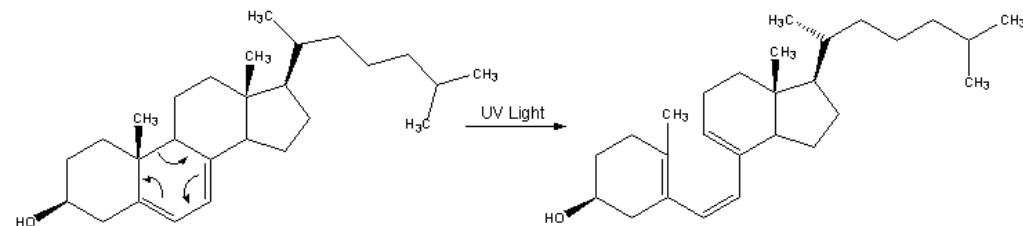


Leg deformation due to rickets



A family with rickets, France ~1900

Vitamin D can be synthesised in human skin under UV light exposure by photolyzation



Photolyzation of 7-dehydrocholesterol to pre-vitamin D3

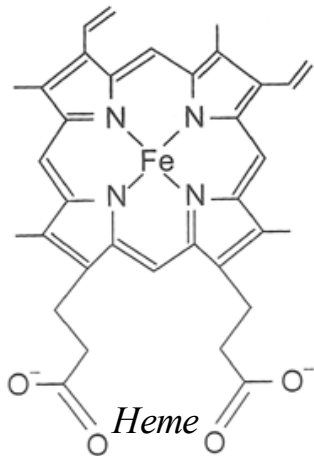
Hans Fischer (*27.7.1881, +31.5.1945)



German Chemist and MD

1925 studies the structure and constituents of porphyrins

1926 first synthesis of porphyrins



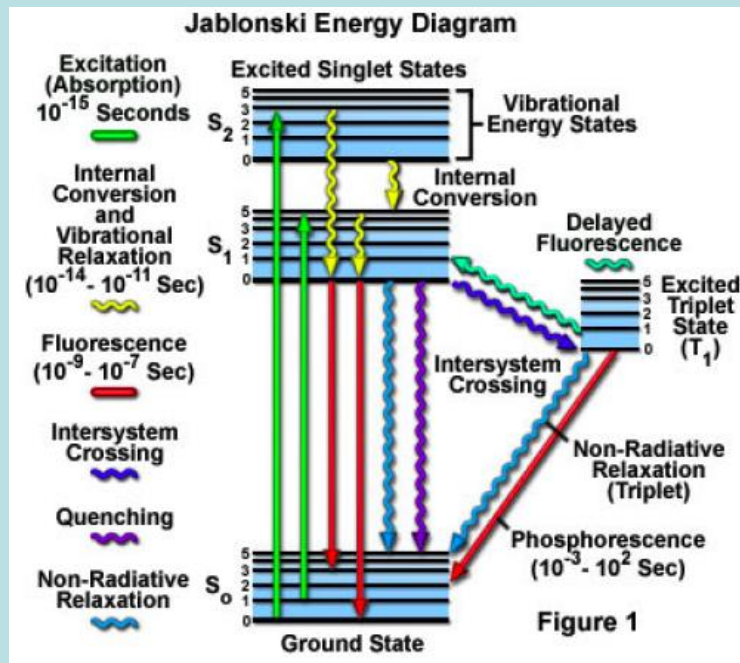
1928 first synthesis of heamin

1930 Nobel Prize "for his researches into the constitution of haemin and chlorophyll and especially for his synthesis of haemin".

Fondamental and Medtech progresses

1935

Alexander Jablonski establishes his Jablonski diagram



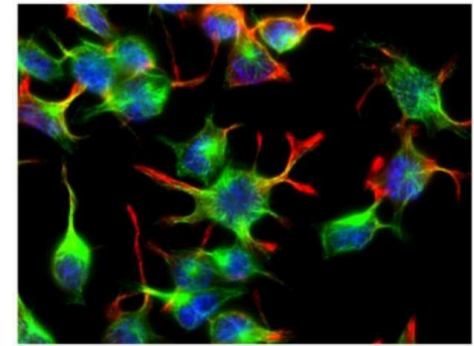
1936

Schindler and Wolf introduce a semi-flexible gastroscope

Middle of the 20th century

1950

A. Hewett Coons and Melvin Kaplan develop the immunofluorescence technique in biology



*Immunofluorescence:
Rat basophilic leukemia cells*

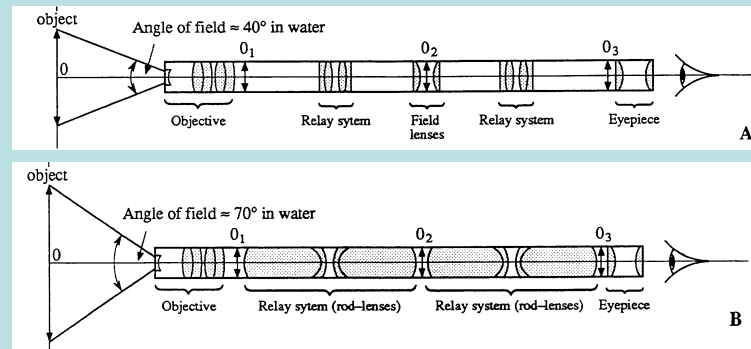
1952

Forestier uses a quartz rod inserted into a steel tube placed inside a rigid endoscope to guide light to the endoscopic site => external light source)

Progresses in endoscopic optics

1954

H.H. Hopkins develop an improved optical system based on glass rods interspaced by air lenses, instead of standard lenses (Hopkins optics)



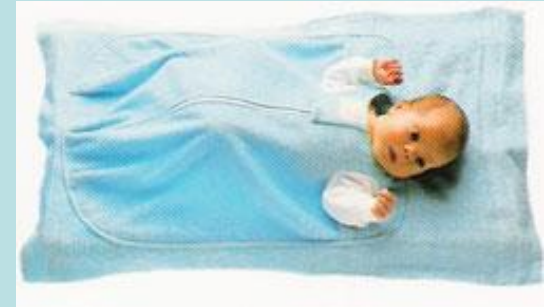1954

A. van Heel and H.H. Hopkins: imaging fiber bundles

1954

A. van Heel invents the cladding of fiber-optical cables

Endoscopy and Neonatal Jaundice



1957

Neonatal jaundice: benefit of blue light exposure on neonatal jaundice is discovered by accident

1959

Brian O'Brien and Narinder Kapany: fibroscope

Neonatal Jaundice (Ictère "jaunisse")

Common condition in newborn (about 50%)

Origin:

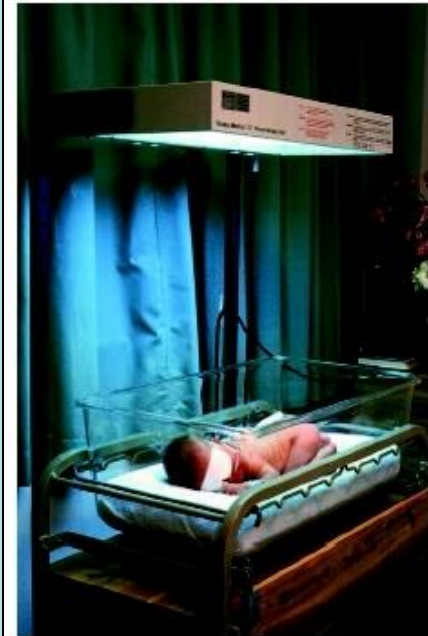1. breakdown of fetal hemoglobin (replaced with adult hemoglobin)
2. immature hepatic metabolic pathways
⇒ accumulation of unconjugated bilirubin
⇒ **neurotoxicity**

Symptoms:

yellow colour of skin and sclera

Phototherapy:

photoisomerization and photooxidation of unconjugated bilirubin to its watersoluble, i.e. excretable, conjugated form



The first lasers

1960

Theodore H. Maiman: first working ruby laser (694 nm, pulsed operation)

1961

A. Javan: first HeNe laser



Tissue imaging and lasers in medicine

1961

Novotny and Alvis: retina angiography with fluorescein

1961

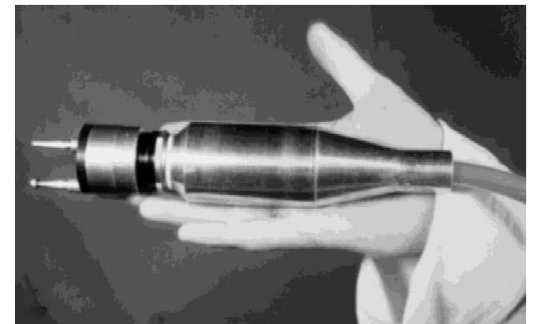L. Goldman, MD "Father of laser surgery" recognises the potential for lasers in medical applications

"If you don't need a laser – don't use it."



1962

first black and white television camera for endoscopy



Major "Medtech" breakthrough

1965

first surgical CO₂ laser

1968

S. Ikeda: flexible bronchoscope



1969

W. Boyle and G. Smith invent the CCD (Camera)

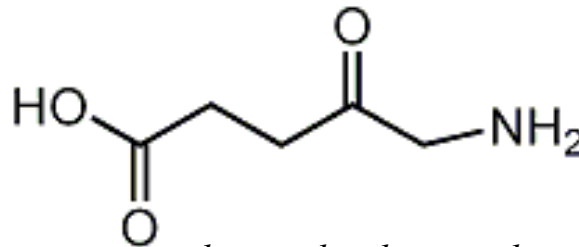
"Medtech" and Pharma progresses

1985

First videoendoscopy system with CCD detectors at the distal tip are investigated for clinical use

1987

Malik and Lugaci use d-aminolevulinic acid (ALA) as photosensitising and tumor photodetection agent.



d-aminolevulinic acid

"Medtech" and Pharma progresses

1990

633 nm diode laser commercialised

1990/92

Kennedy: first clinical use of topical aminolevulinic acid (ALA) for fluorescence detection and Photodynamic Therapy (PDT)

"Medtech" progress

1990

First Optical Coherent Tomography (OCT) image

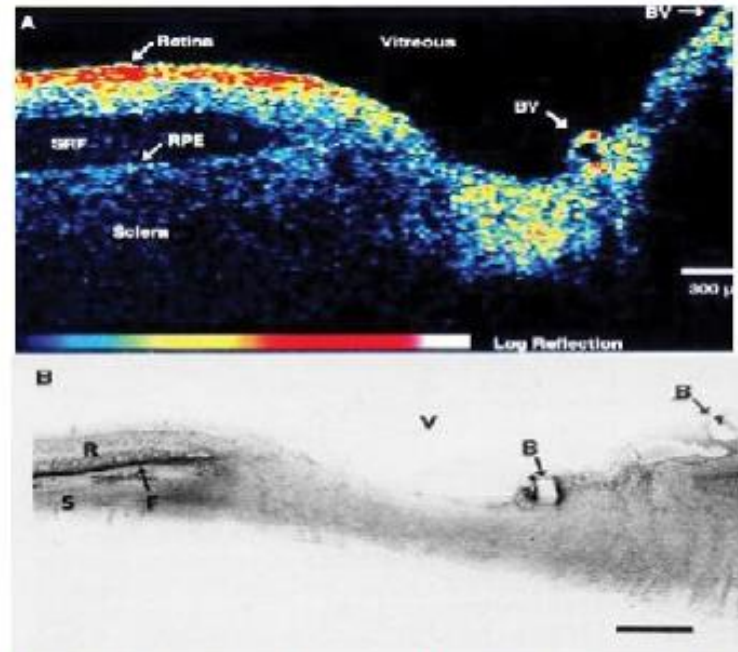
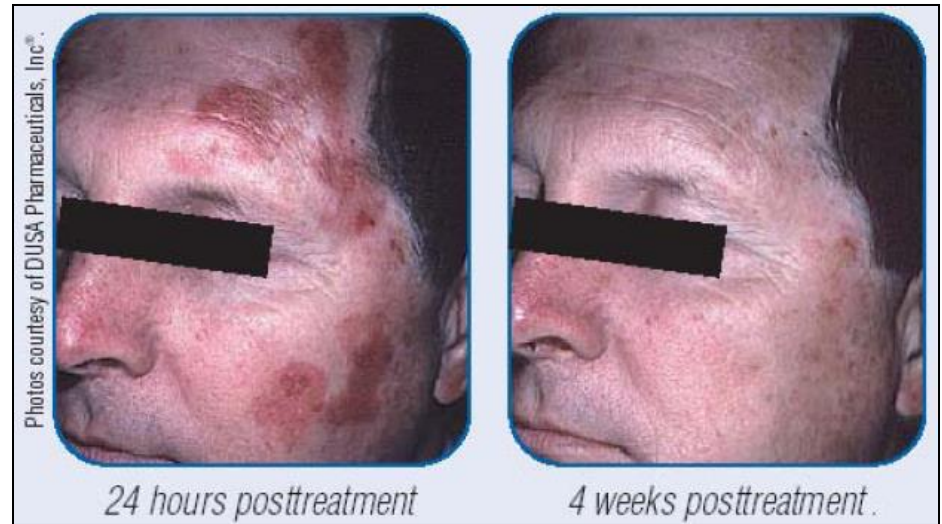

Figure 1. The first OCT image of the retina *ex vivo* and corresponding histology. Note the detachment of the retina, common in post-mortem eyes.

Actinic Keratosis and basocellular carcinoma treated by PDT

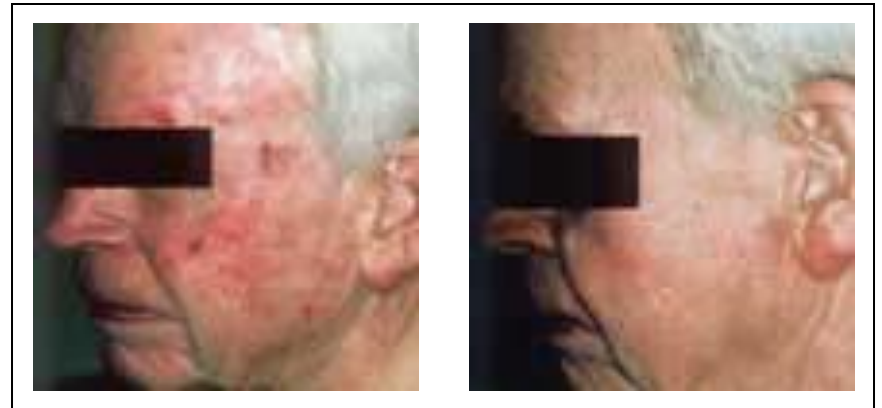2000

Levulan®
(ALA) topically



2001

Metvix®
(methyl-ester ALA)
topically

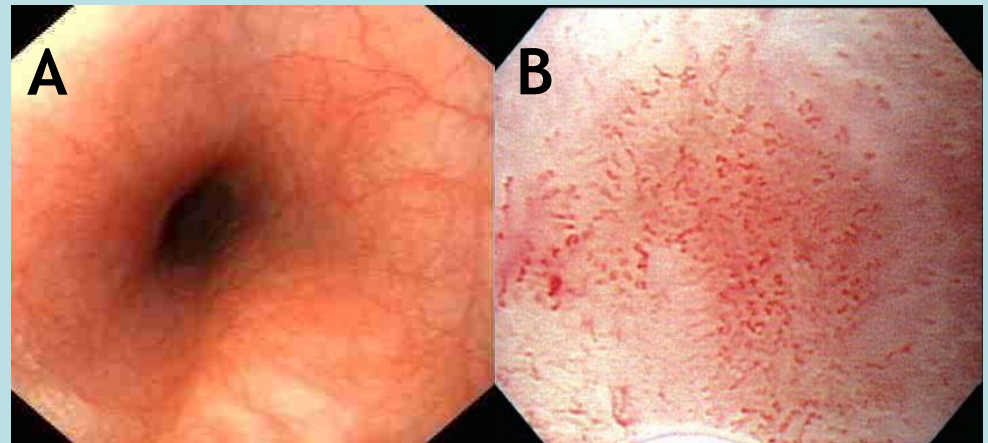


Other present/future fields include: High magnification endoscopy (gastroenterology)

- Observation of the intrapapillary loops (IPCL)

- dilatation
- weaving
- changes in caliber
- differences in shape

XEC300 & XE120, Olympus Corp., Tokyo, Japan



A) Normal view of the esophagus.

B) Magnification view of carcinoma in situ (m1; 100 \times).

Kumagai et al. (2006) *Digestive Endoscopy* 18, 165-172

Other present/future fields include: Narrow band imaging (NBI)

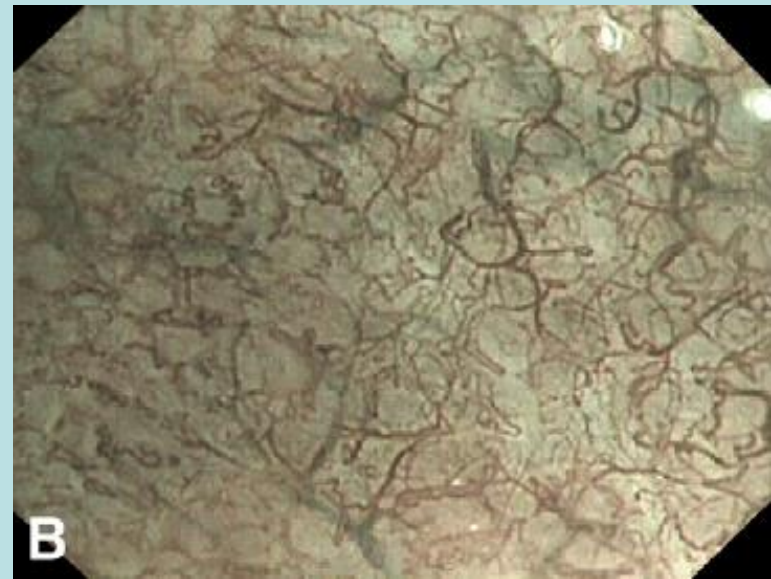
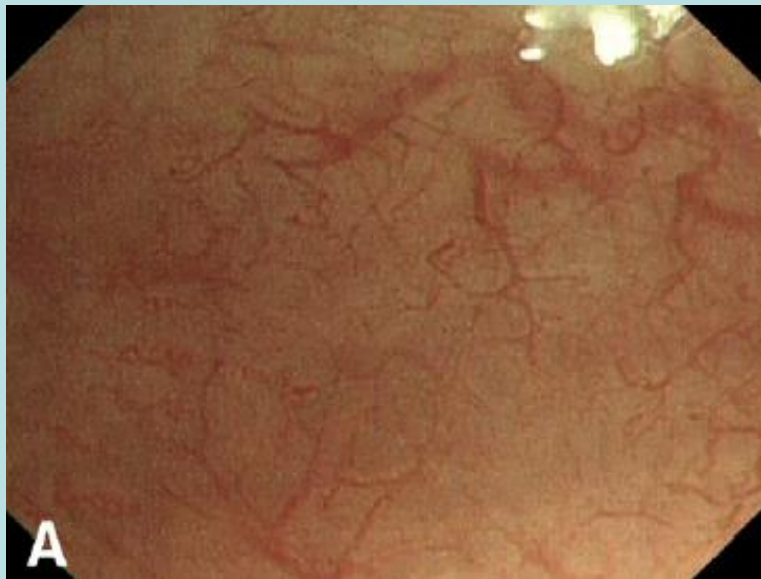
TABLE 1. Narrow band filters and display of 2-band versus 3-band NBI systems

NBI systems	NBI filters (center wavelength) (bandwidth)	Video channels used for image display
2-Band RGB sequential and color CCD NBI	415 nm (30 nm) 540 nm (20 nm)	Blue and green Red
3-Band RGB sequential NBI*	415 nm (30 nm) 445 nm (30 nm) 500 nm (30 nm)	Blue Green Red

*Prototype.

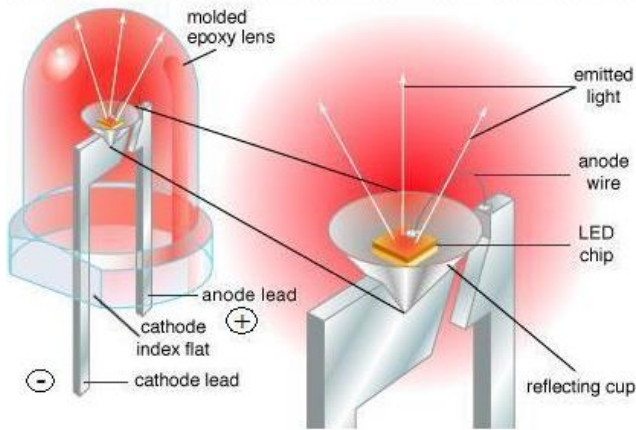
**Other present/future fields include:
Narrow band imaging (NBI)**

Figure 1. Magnified (A) white-light versus corresponding (B) NBI images of nondysplastic Barrett's mucosal vascular pattern. Under NBI, capillaries appear brown, whereas deeper vessels appear cyan.




Wong Kee Song et al., GASTROINTESTINAL ENDOSCOPY, Volume 67, No. 4 : 2008

Other present/future fields include: Light Emitting Diodes (LEDs)




- ✓ Small
- ✓ Powerful
- ✓ High efficiency
- ✓ Cheap
- ✓ Robust
- ✓ Long lifetime
- ✓ Different wavelengths
- ✓ Relatively bright

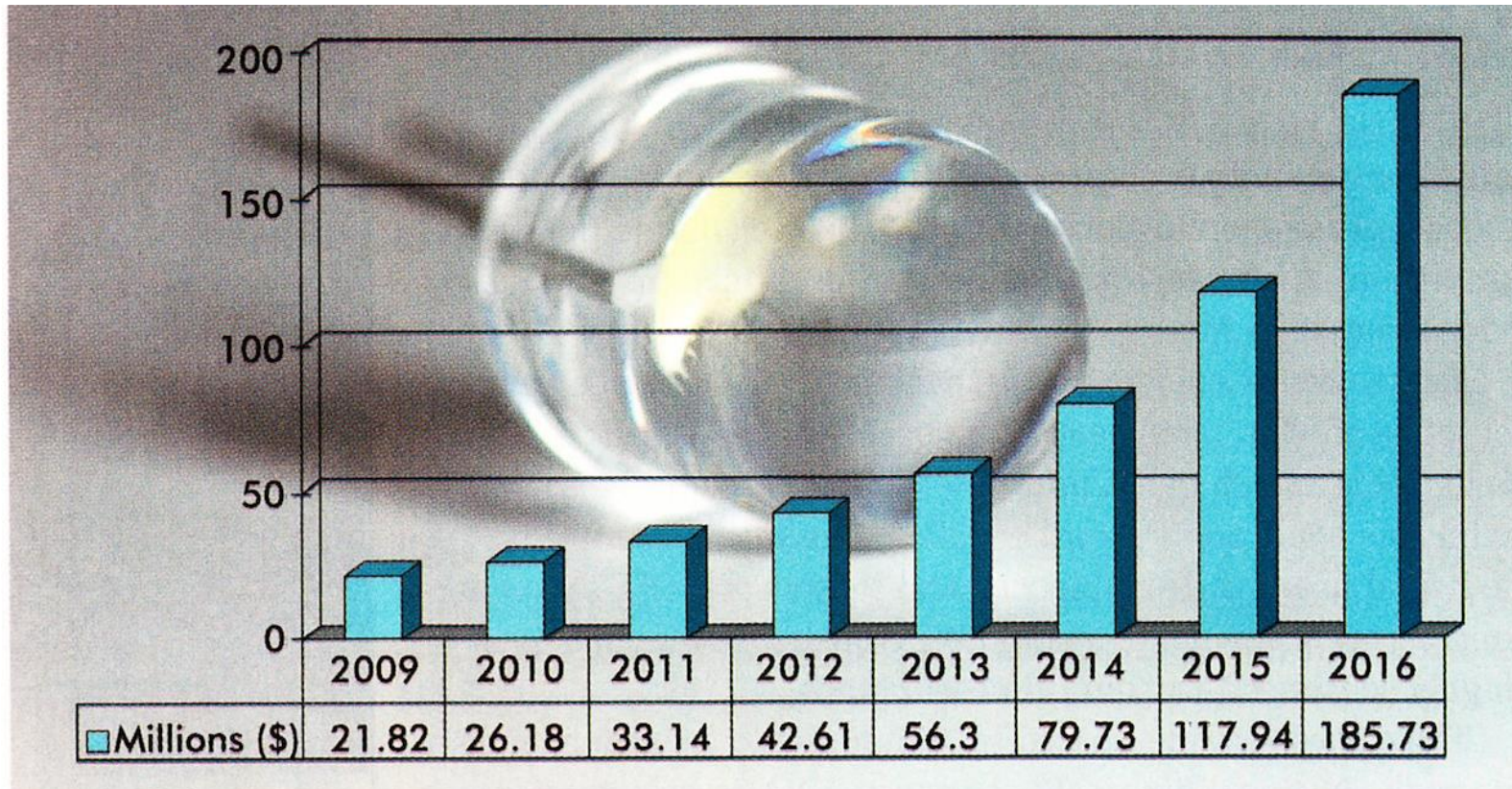


Inside the PiliCam

1. Optical dome
2. Lens holder
3. Lens
4. Illuminating LEDs (light-emitting diodes)
5. CMOS (complementary metal oxide semiconductor) imager
6. Battery
7. ASIC (application-specific integrated circuit) transmitter
8. Antenna



Other present/future fields include: Light Emitting Diodes (LEDs)



The global consumption value of LEDs in test/measurement and medical/science devices is expected to rise to \$185.73 million in 2016, with an average annual growth rate of 35.8 percent over the period from 2009. Courtesy of ElectroniCast Consultants.

Partial list of some of the biomedical applications for laser diodes

Applications	Type	Wavelength (nm)																		
		405	450	635	652	670	689	752	766	794	810	915	940	980	1064	1210	1320	1470	1550	1940
Aesthetics	Acne Treatment		X															X		
	Hair and Wrinkle Remover								X		X	X			X	X				
	Laser Skin Resurfacing										X	X								
	Lipolysis														X	X				
	Pigmented Lesions										X		X	X						
	Tooth Whitening										X			X						
	Varicose Vein Removal												X							
Diagnostics	MRI									X										
Photodynamic Therapy	Aged-Related Macular Degeneration						X	X												
	Cancer Treatment			X	X	X														
	Wound Healing	X												X						
Surgical Treatment	Dental Treatment													X						
	Endovenous Treatment											X								
	General Surgery													X	X		X	X	X	
	Microsurgery													X	X					
	Urology													X			X	X		

..... to be continued !

- Nanoparticles-based delivery of photosensitizers
- Light-induced immunomodulation
- Photobiomodulation (LLLT)
- 2 hv tissue characterization
- ...

The availability of lasers, sensitive detectors and/or advanced signal acquisition/processing/analysis techniques are at the origin of numerous approaches used in **microscopy** !

- Fluorescence Correlation Spectroscopy (**FCS**)
- Fluorescence Lifetime Imaging (**FLIM**)
- Fluorescence Recovery After Photobleaching (**FRAP**)
- Light sheet fluorescence microscopy (**LSFM**)
- Confocal microscopy (**CFM**)
- ...

The availability of lasers, sensitive detectors and/or advanced signal acquisition/processing/analysis techniques are at the origin of numerous approaches used in **microscopy** ! (Cont.)

Super-resolution techniques have gained momentum over the last few years, pushing the limits of light microscopy beyond the classical diffraction limit.

- Structured Illumination (**SIM**)
- Stimulated Emission Depletion (**STED**)
- Stochastic Optical Reconstruction (**STORM**)
-

The **BioImaging and Optics Core Facility (BIOP-EPFL)** is active through multiple teaching programs.

Therefore, these microscopy approaches will not be addressed in this course!

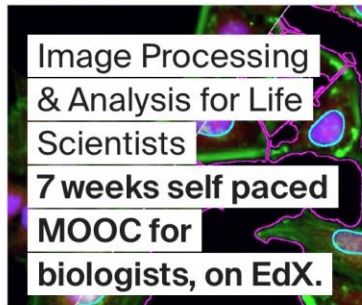
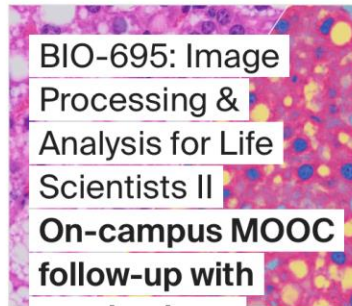


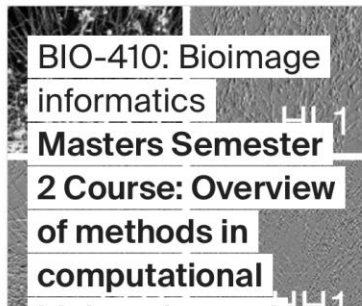
Image Processing & Analysis for Life Scientists
7 weeks self paced
MOOC for biologists, on EdX.



BIO-695: Image Processing & Analysis for Life Scientists II
On-campus MOOC follow-up with emphasis on



MICRO-562: Biomicroscopy II
Masters Semester
2 Course with practical sessions at the BIOP.

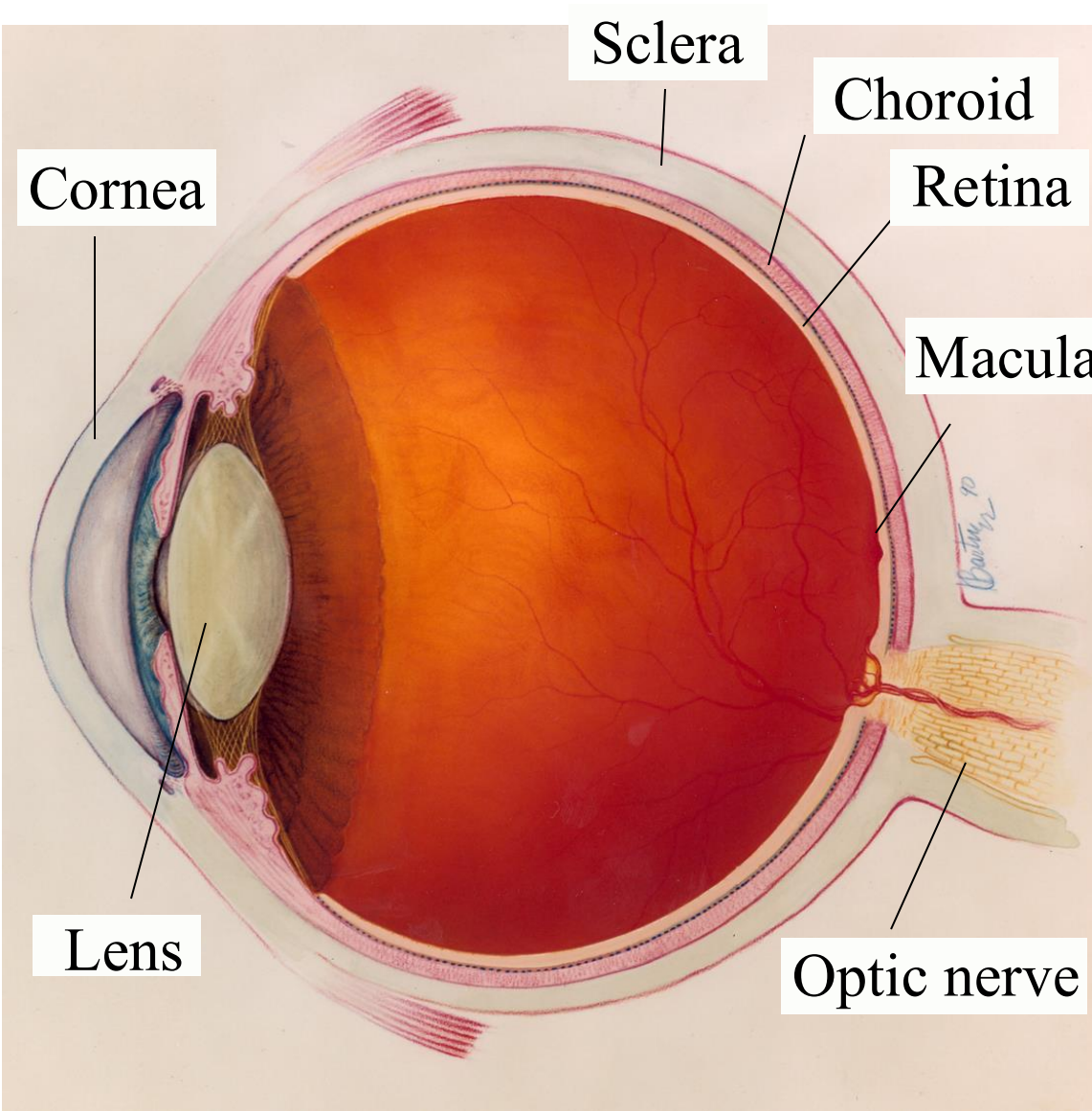


BIO-410: Bioimage informatics
Masters Semester
2 Course: Overview of methods in computational bioimaging and bioimage analysis



BIO-659: Advanced Light Microscopy
Life Science
2 ETCS Credit course on advanced light microscopy

2. History



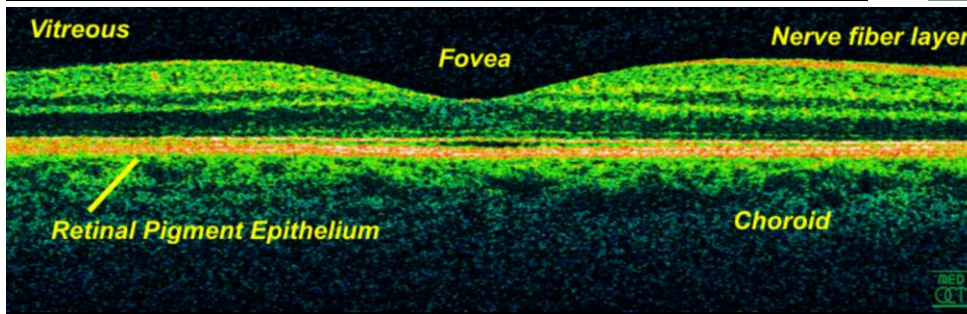
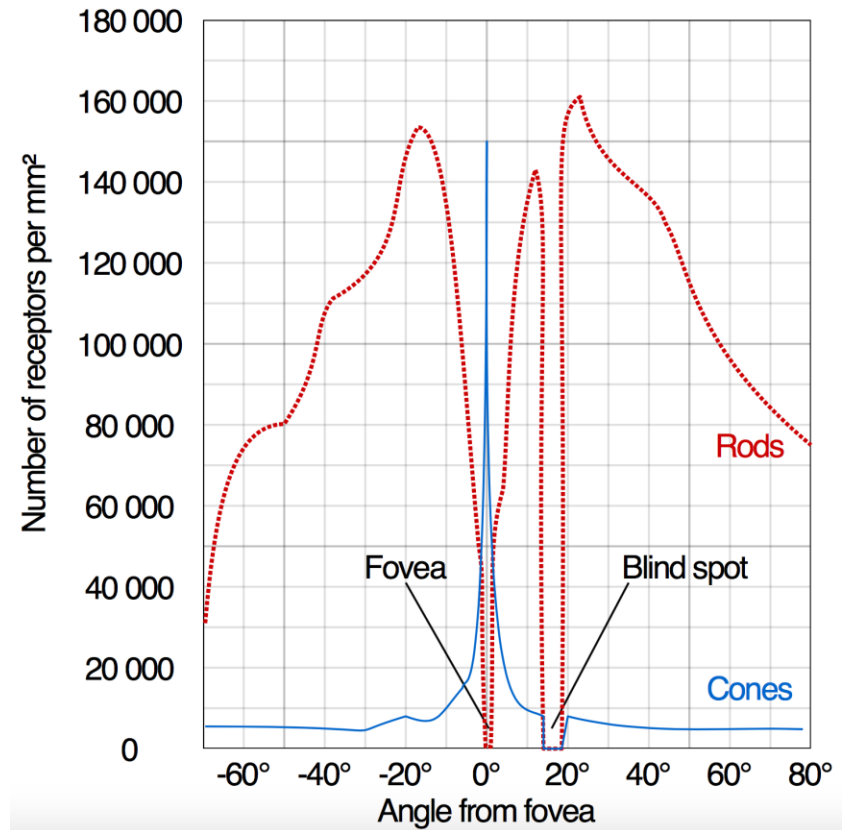
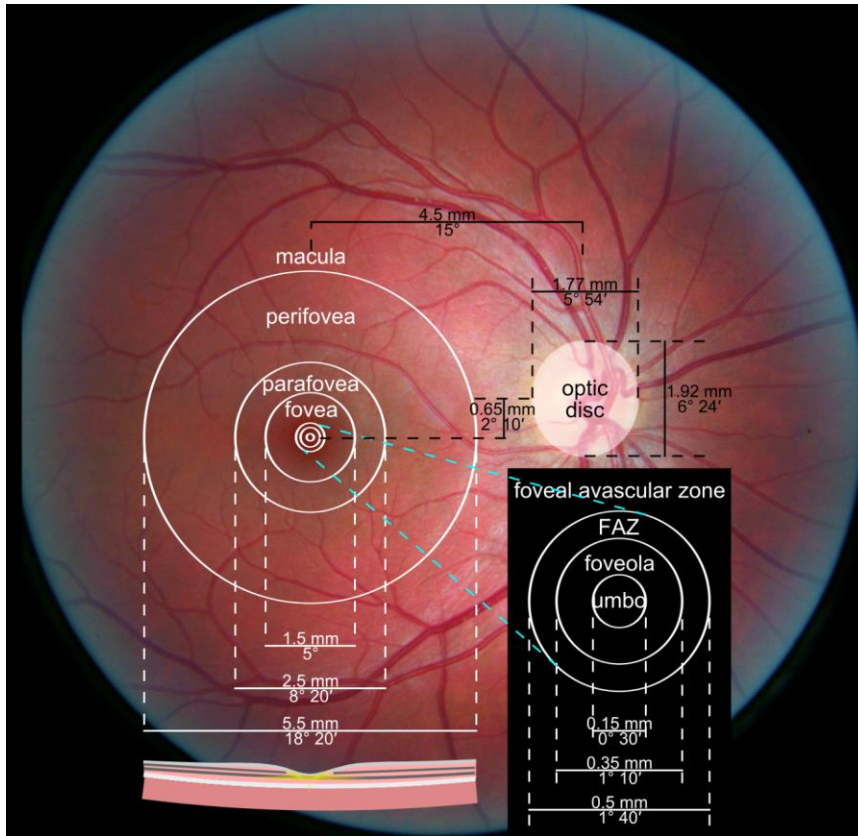
An interesting case:
(A therapeutic application of photomedicine)

**Treatment of age-related
Macular degeneration by
photodynamic therapy
With Visudyne®**

**First studies: early 90's
First approval: 1999**

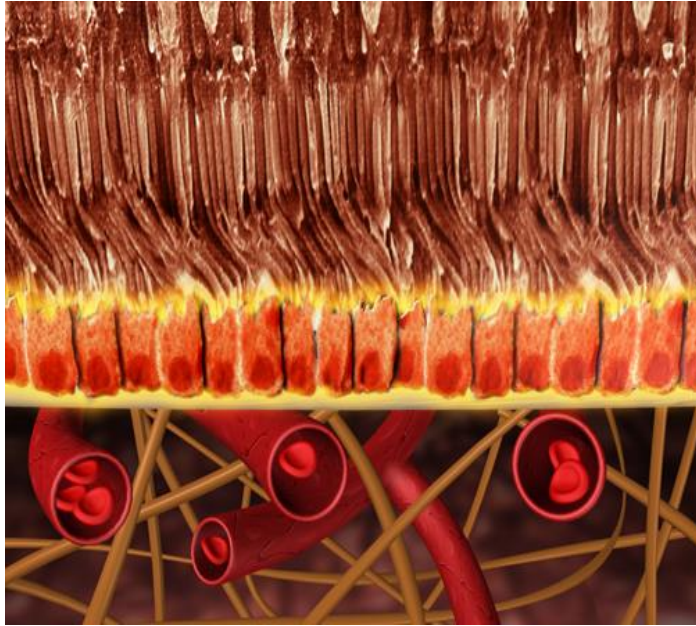
*Anatomy of the
human eye*

Location of the macula



OCT cross-section image at 800 nm

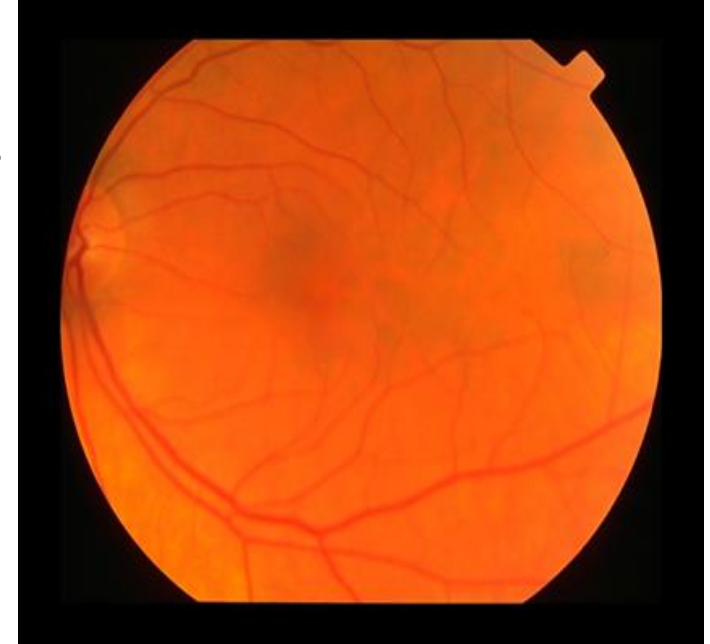Normal retina



Photoreceptors

RPE

Choroid



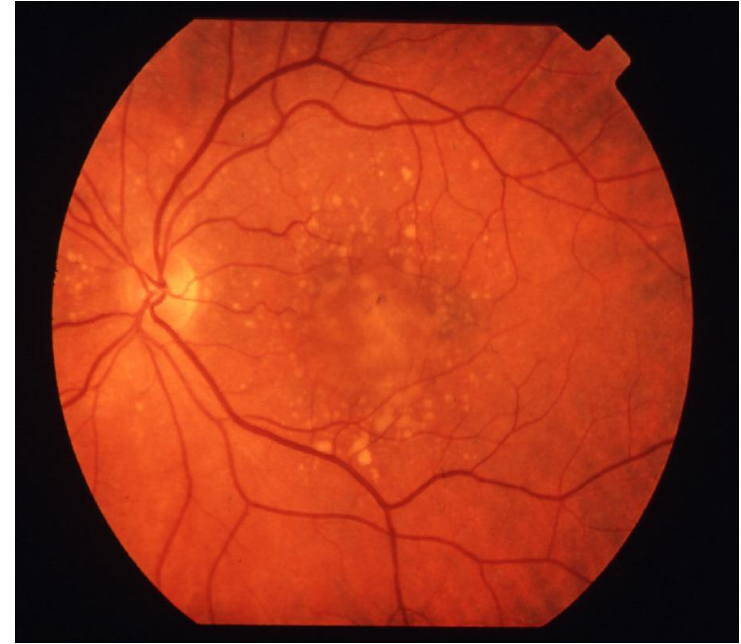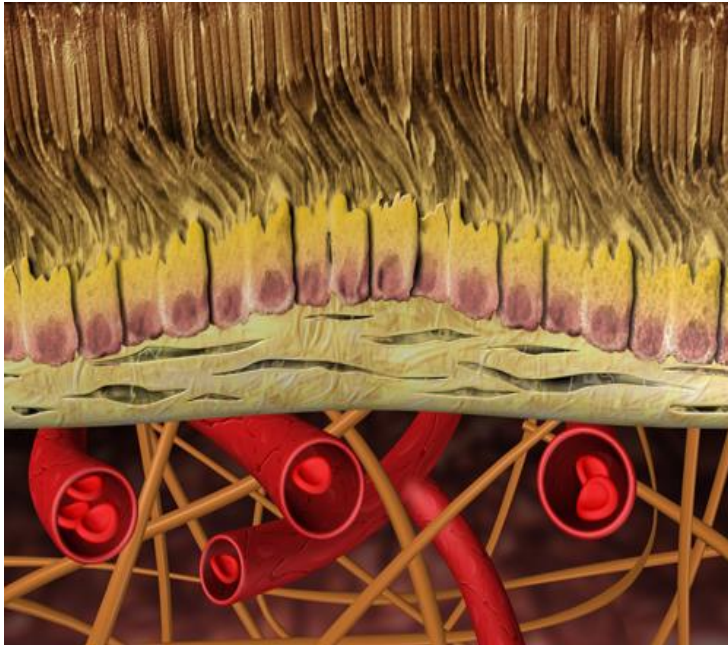
fundus photograph

Vision = high metabolic activity

Retinal Pigmented Epithelium (RPE): major role in nutrition + protection

Source: Novartis Ophthalmics

Aging of macula



fundus photograph

Drusen: accumulation of lipofuscin

Bruch's membrane thickens + calcification

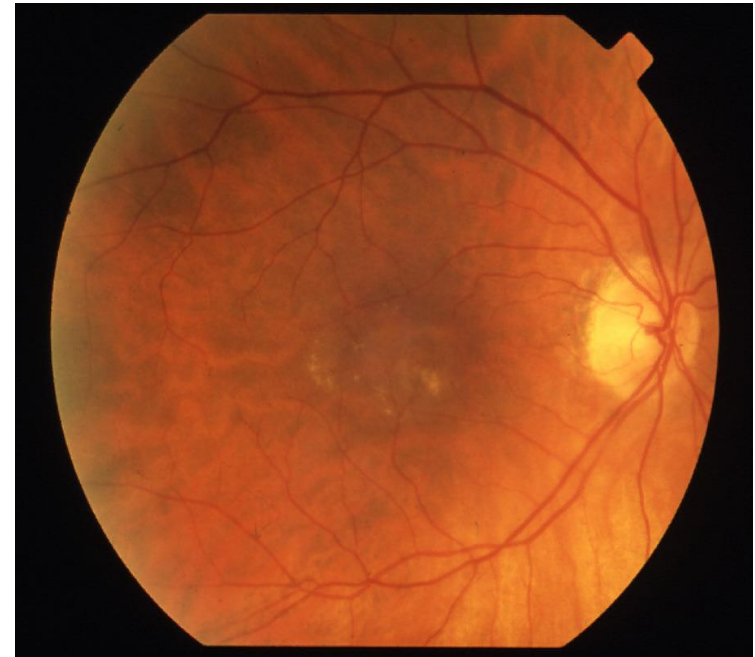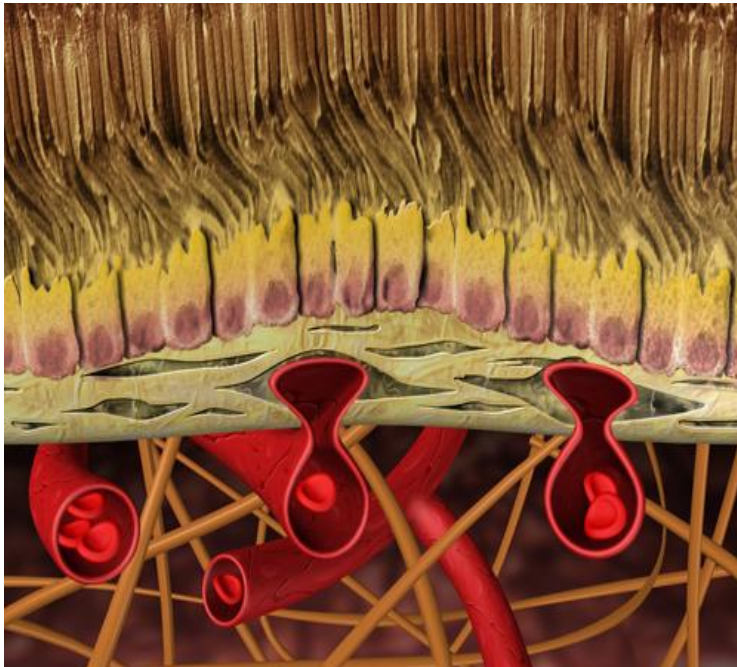
Less choriocapillaris

Rupture of blood-retina barrier

Source: Novartis Ophthalmics

Aging of macula

**One form of AMD:
Bruch's membrane penetration
by choroidal neovessels (CNV)**

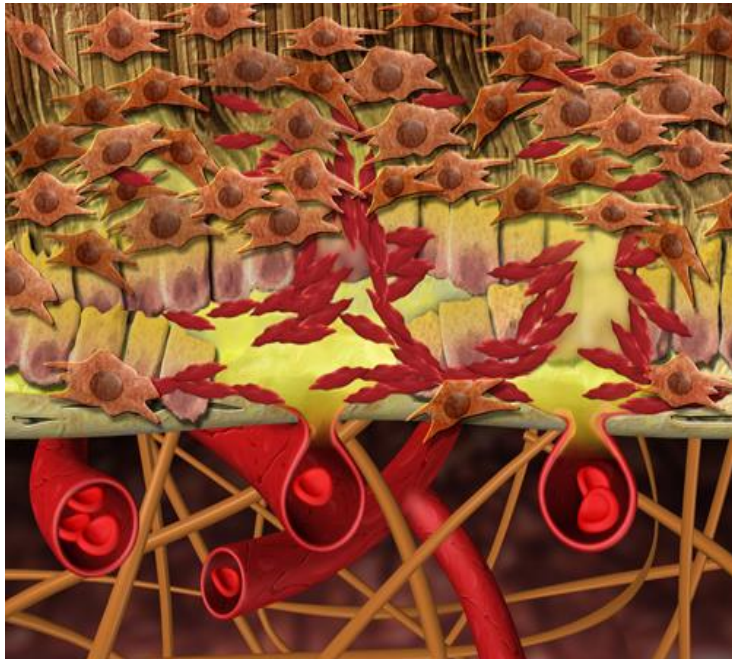


fundus photograph

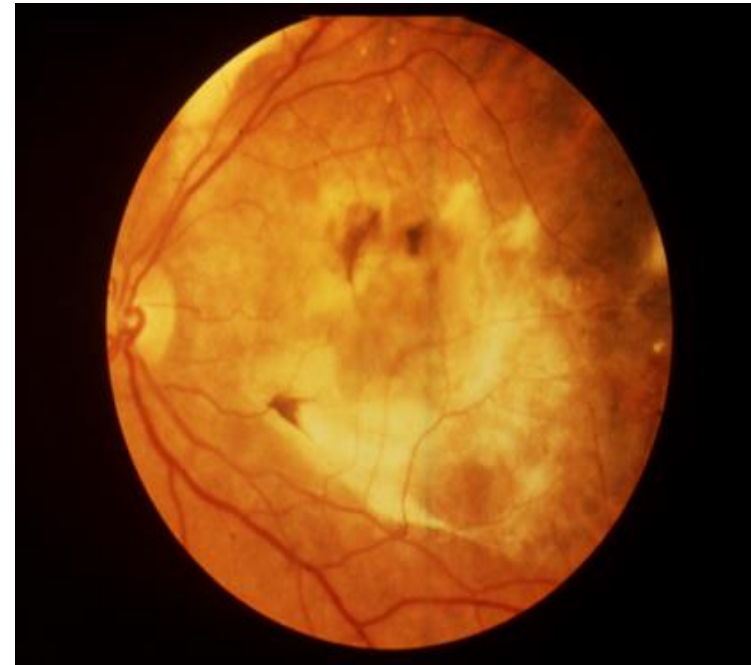
Source: Novartis Ophthalmics

Formation of disciform scar

⇒ **Vision loss**



**Fibroblasts
+
Neovascular
Endothelial
cells**



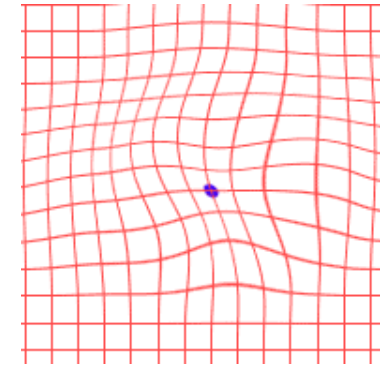
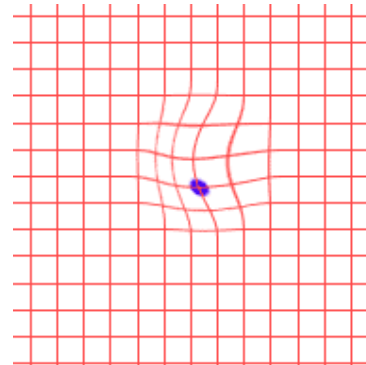
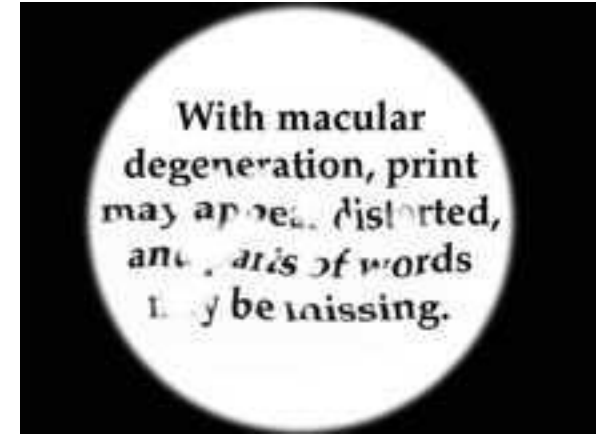
fundus photograph

Source: Novartis Ophthalmics

Normal vision



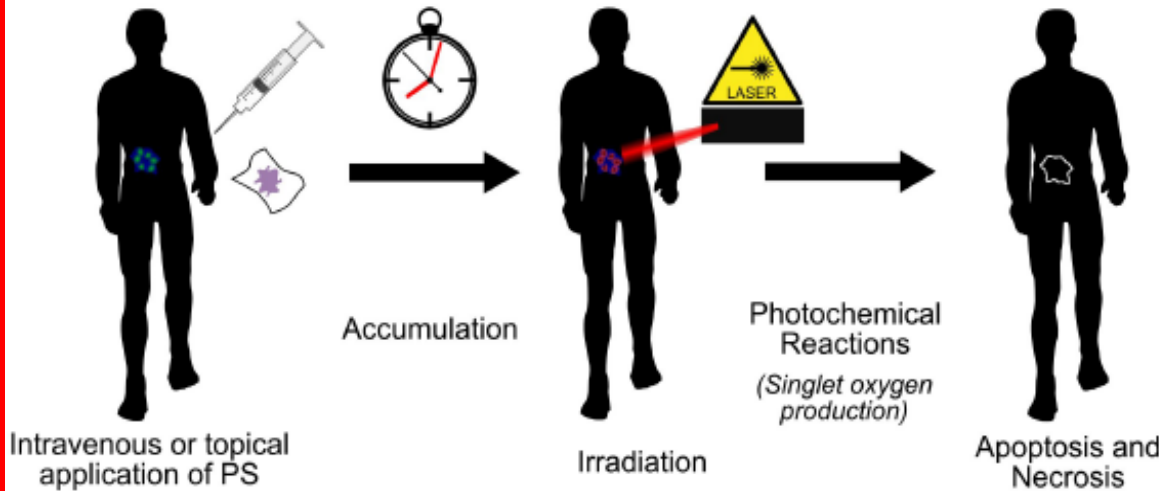
Vision with (AMD)



Amsler grid

Photodynamic Therapy (PDT)

PDT is a well established technique that is effective in treating several non malignant and malignant conditions



Three main components:

1. **Drug:** photosensitizer (PS)
2. **Light:** energy source that activates the drug
3. **Oxygen:** interacting with the excited PS, induce cell death

Advantages:

- *Good selectivity in certain cases*
- *Can be repeated*
- *Minimally invasive*
- ...

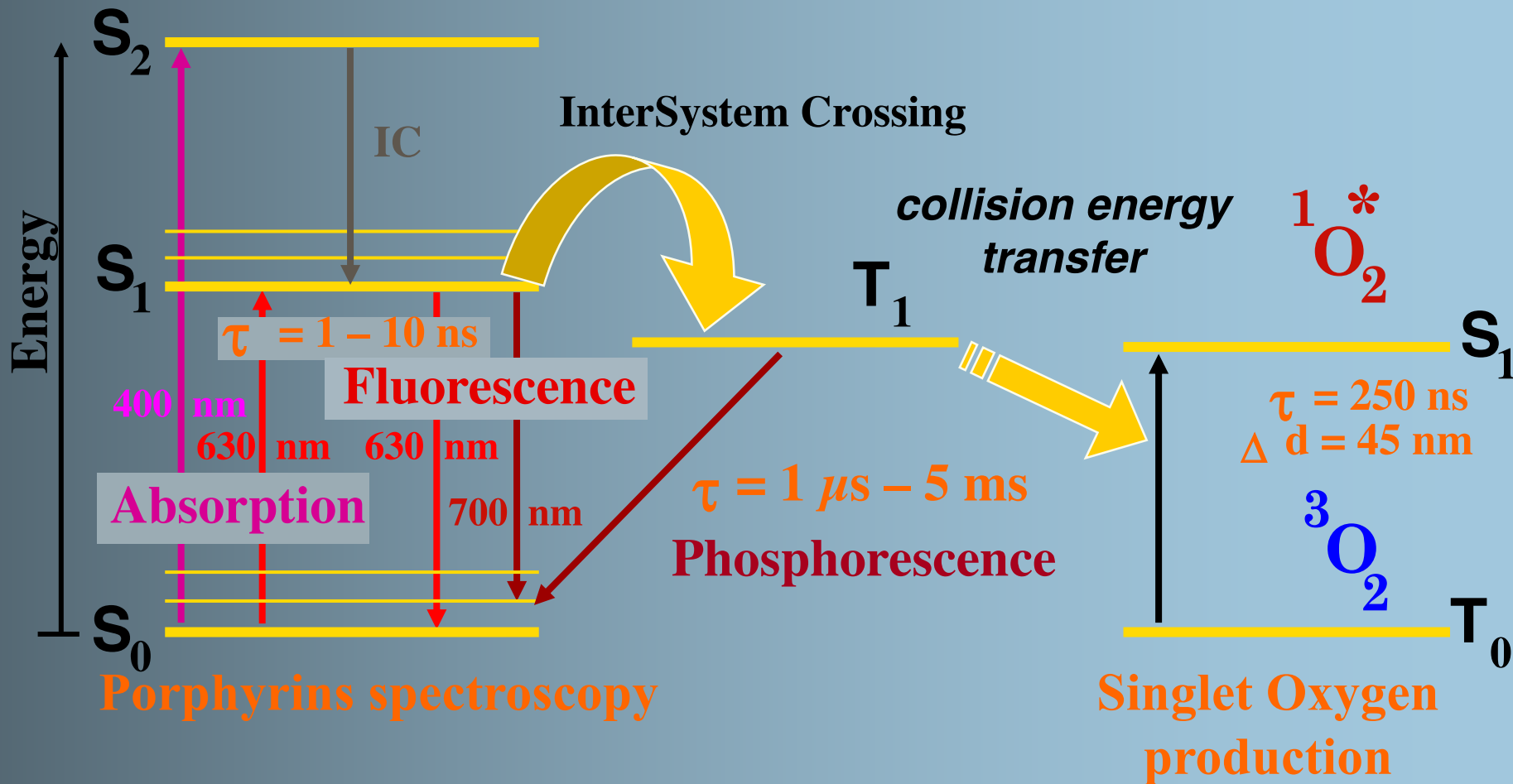
Drawbacks:

- Delayed response
- Skin photosensitization
- Only small/superficial volumes can be treated
- Inter and intra patient fluctuation
- ...

Photophysical Processes in:

Fluorescence detection

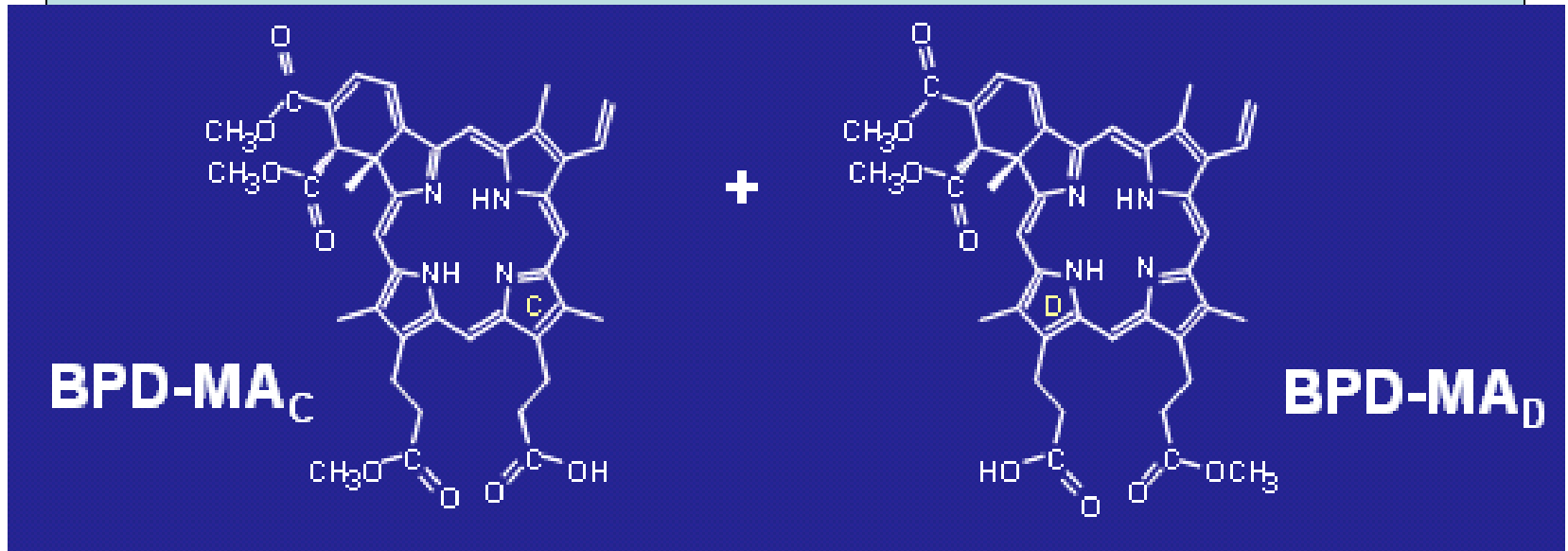
Photodynamic Therapy



Collisions with O_2 shorten the PS's triplet state lifetime τ

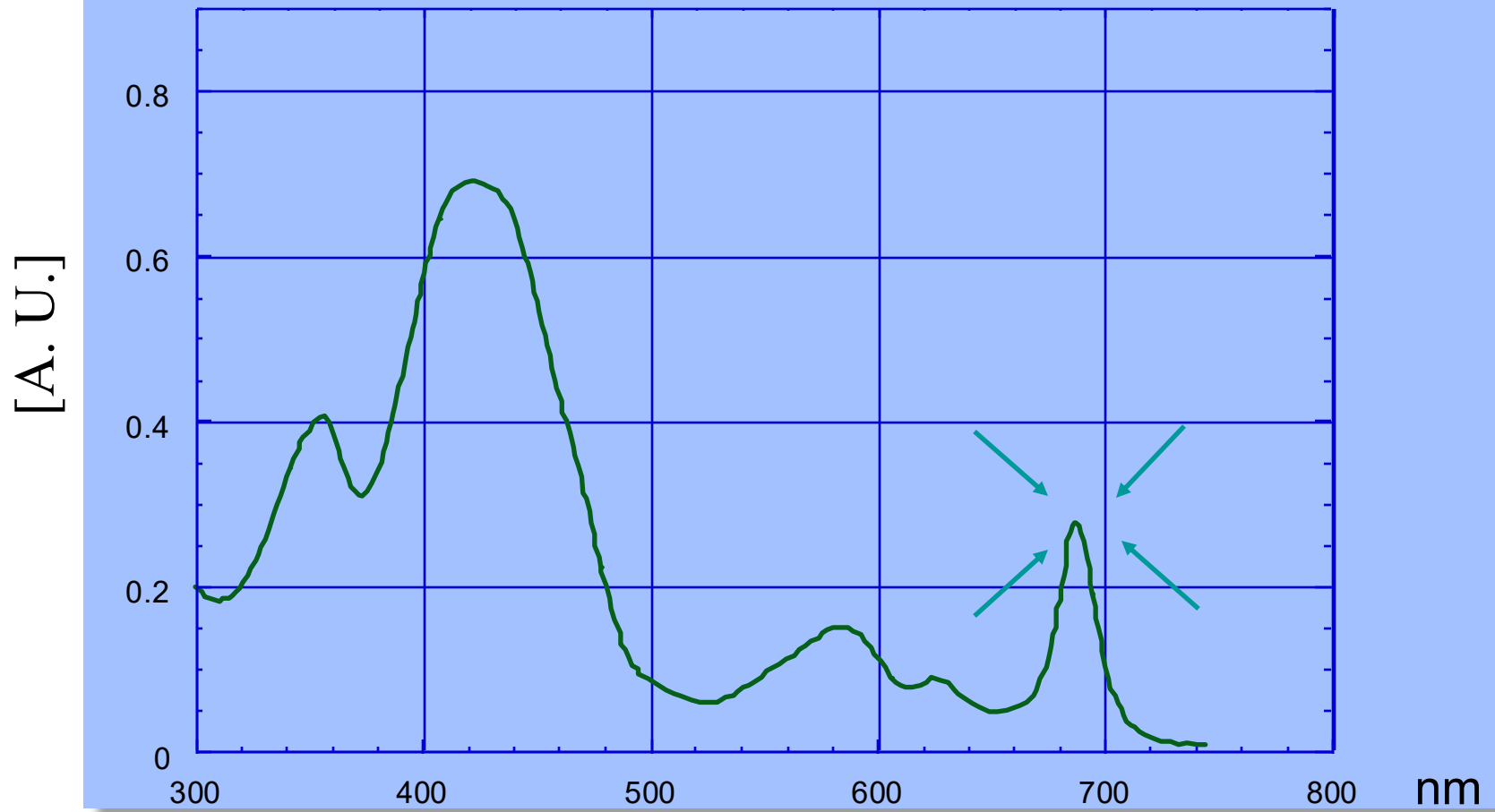
Visudyne[®] is an angio-occlusive photosensitizer

Visudyne (verteporfin) exists in an equal mixture of two pharmacologically active benzoporphyrin-derivative monoacid (BPD-MA) regioisomers

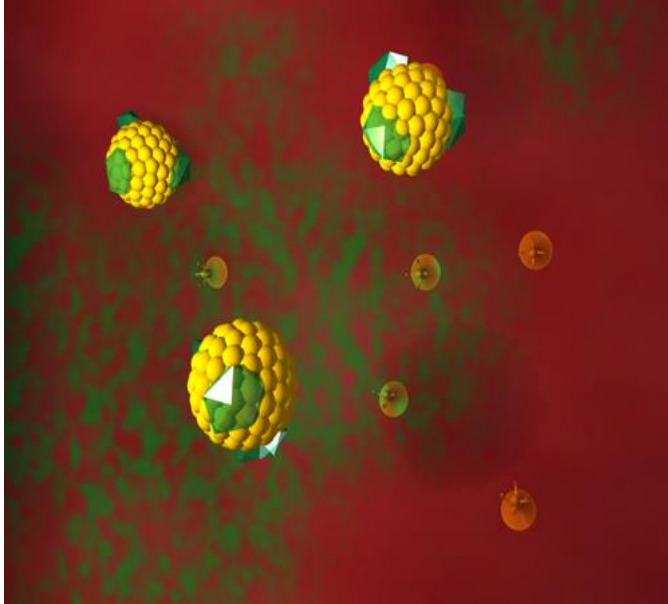


Houle JM, Strong A. *J Clin Pharmacol.* 2002;42:547–557.

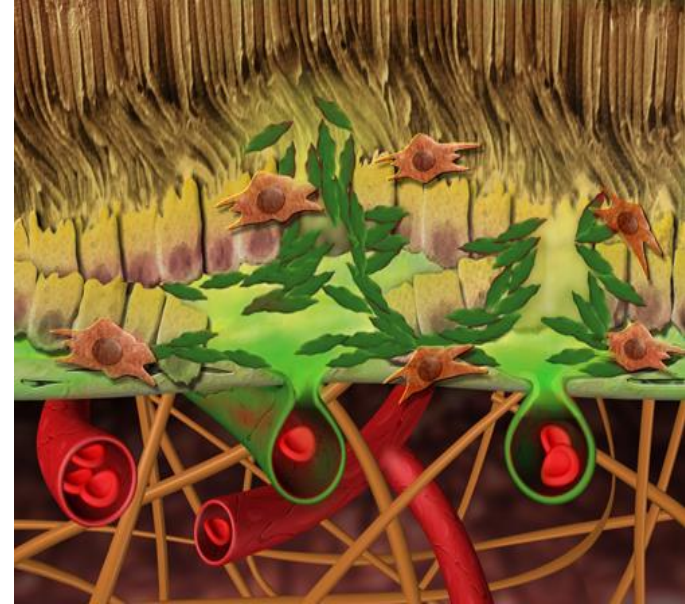Absorption spectrum of Visudyne®



Verteporfin: Mechanism of action



Verteporfin complexes with
LDL

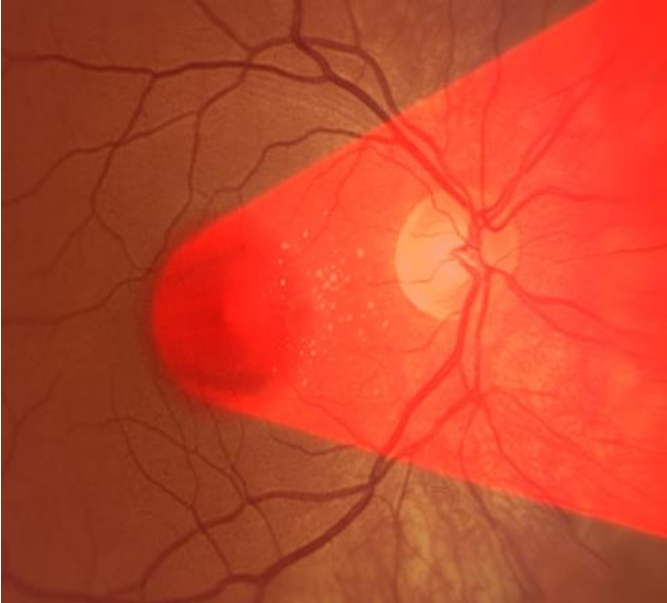


**Dye accumulates in
neovascular tissue**

Source: Novartis Ophthalmics

PDT with Visudyne™

Treatment procedure

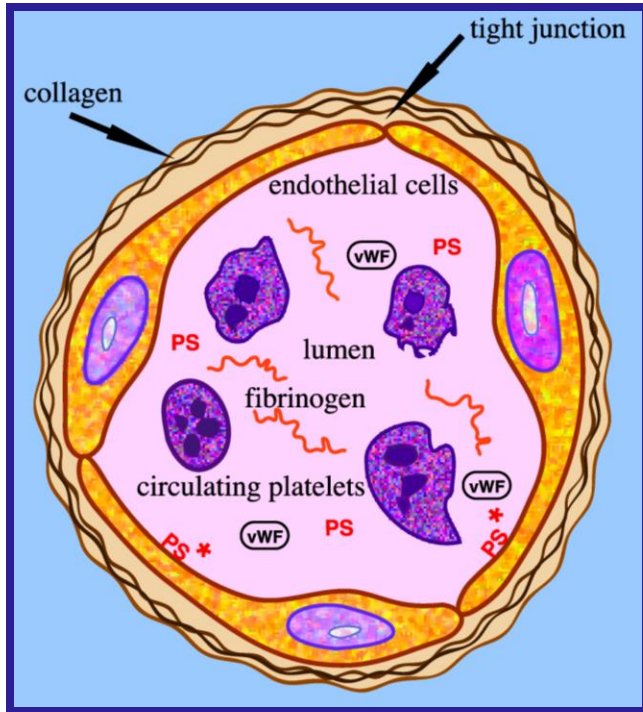


- Drug dose: 6 mg/m²
- Light dose: 50 J/cm² @ 690 nm
- Light dose rate: 600 mW/cm²
- Outpatient procedure

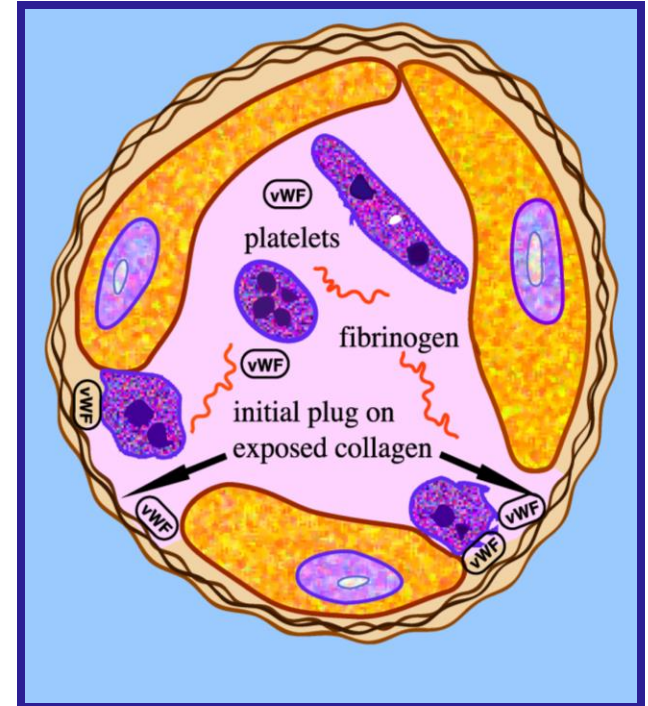
Laser started 15 min
after infusion begins

Source: Novartis Ophthalmics

The short-lived reactive oxygen species cause endothelial cell changes



Cross-section of blood vessel



- Cytoskeleton changes cause rounding and contraction of the vascular endothelial cells.
- Exposure of the subendothelial basement membrane triggers platelet binding and aggregation.

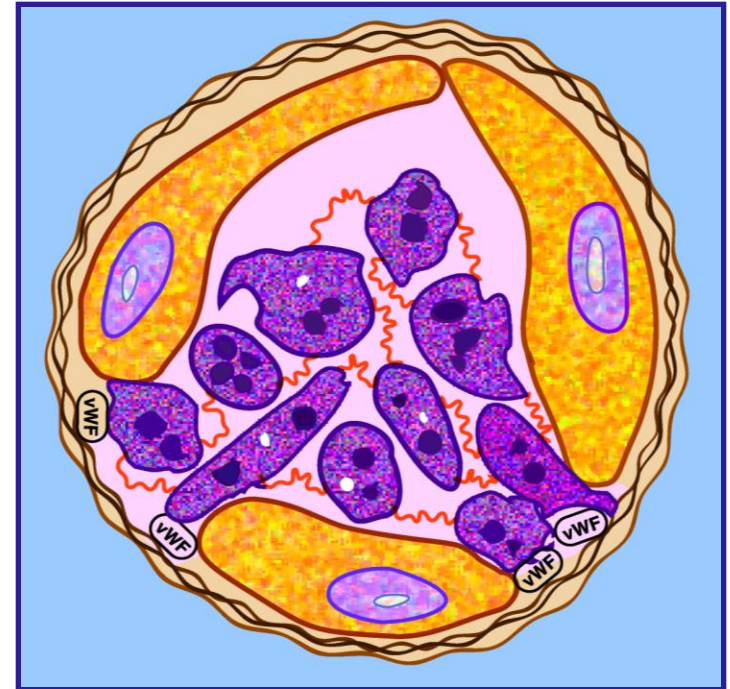
Beaumont P *et al. Arch Ophthalmol.* 2004;122:1546–1547.

Schmidt-Erfurth U, Hasan T. *Surv Ophthalmol.* 2000;45:195–214.

Verteporfin therapy triggers a process leading to neovascular angiocclusion

Cross-section of blood vessel

- The activated platelets adhere to the collagen of the exposed basement membrane
- A fibrin-stabilized plug is formed as the blood clots
- Complete closure of the choroidal neovasculture occurs within 1 day




Beaumont P *et al. Arch Ophthalmol.* 2004;122:1546–1547.

Michels S, Schmidt-Erfurth U. *Invest Ophthalmol Vis Sci.* 2003;44:2147–2154.

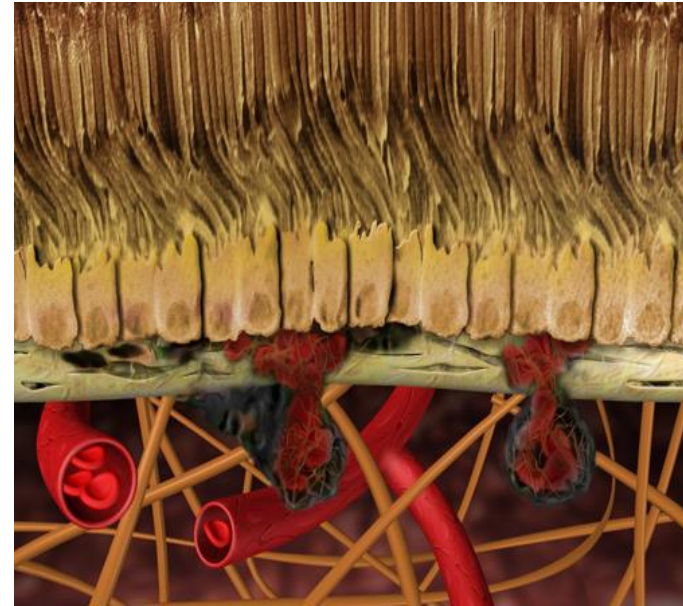
Visudyne US Package Insert. 2005.

Michels S *et al. Invest Ophthalmol Vis Sci.* 2006;47:371–376.

Verteporfin: Mechanism of action



Verteporfin reacts with oxygen after absorption of light



Damaged Choroidal neo-vessels (thrombosis)

Source: Novartis Ophthalmics

Fluorescence angiographies showing the PDT effects

Swissmedic **1999** and FDA **2000** approvals of Visudyne™ for the treatment of Age-related Macular Degeneration (AMD)

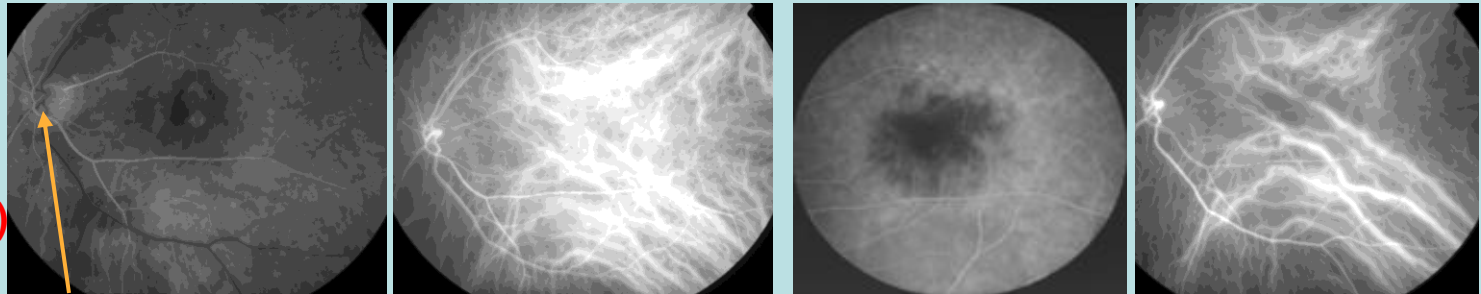
Before PDT

1 week after PDT

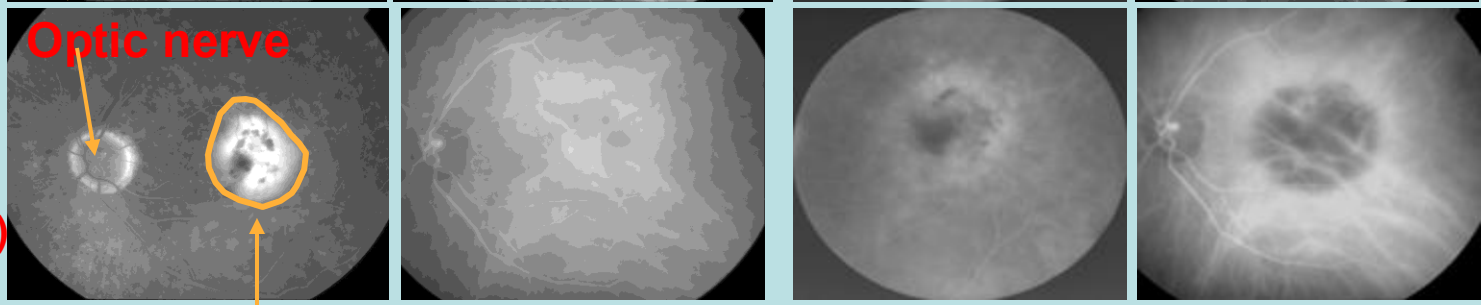
Fluorescein Angiography ICG Angiography

Fluorescein Angiography ICG Angiography

Early Phase (< 1 min.)



Late Phase (> 5 min.)

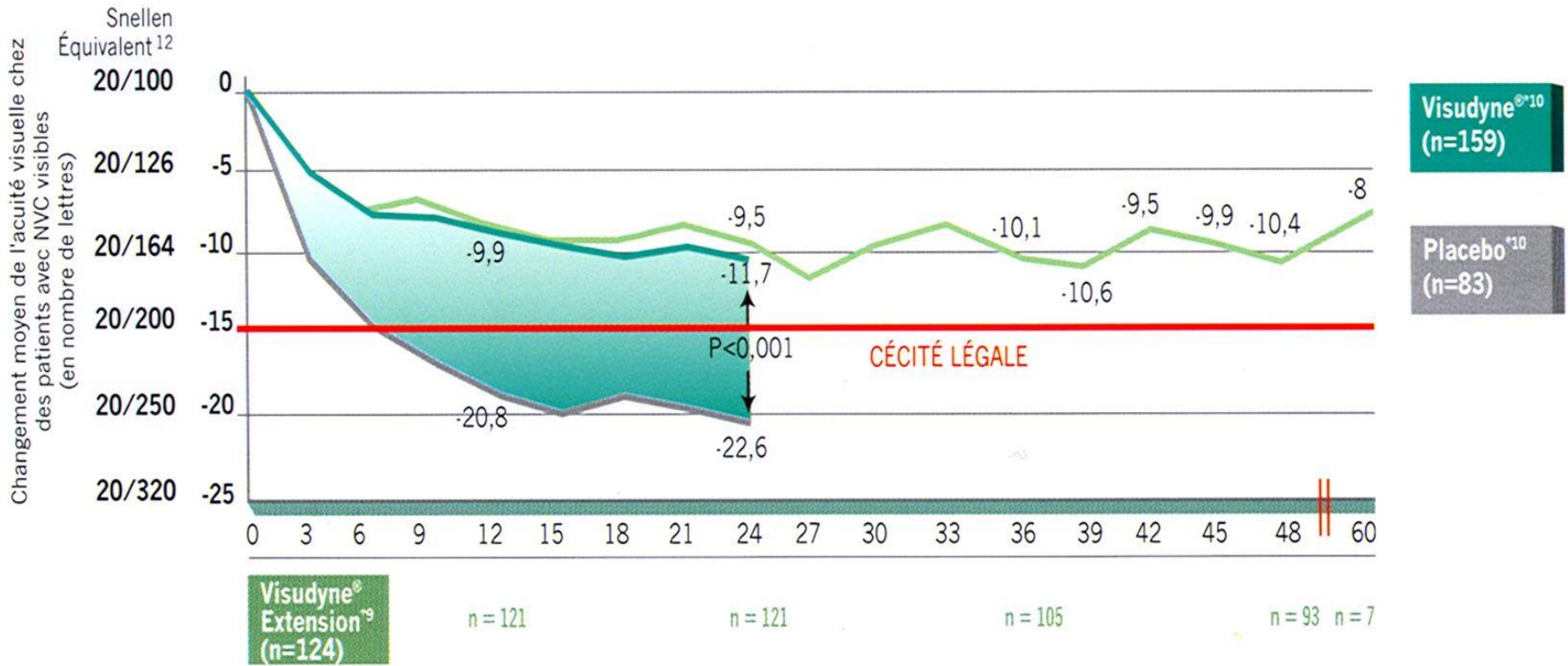


Leaking CNV (predominantly classic)

Source: Dr. M. Sickenberg, Lausanne

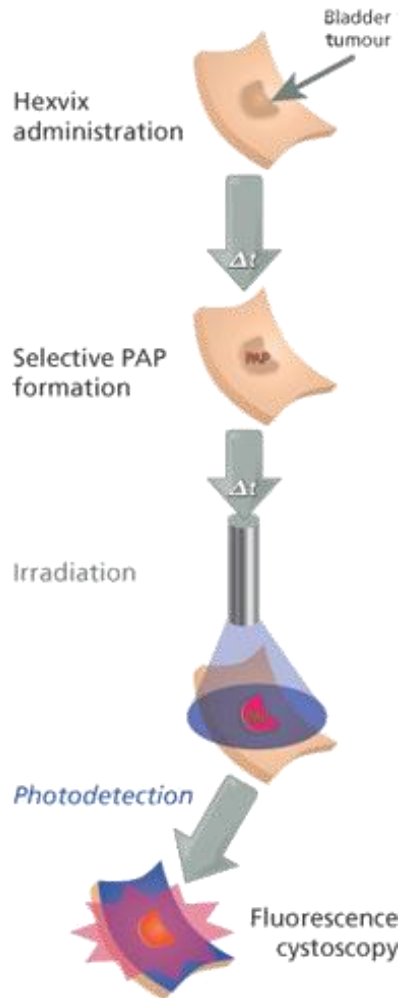
Visudyne® 5 years Follow up

Résultats à 5 ans de l'étude TAP sur l'acuité visuelle.^{1,9,10,11}

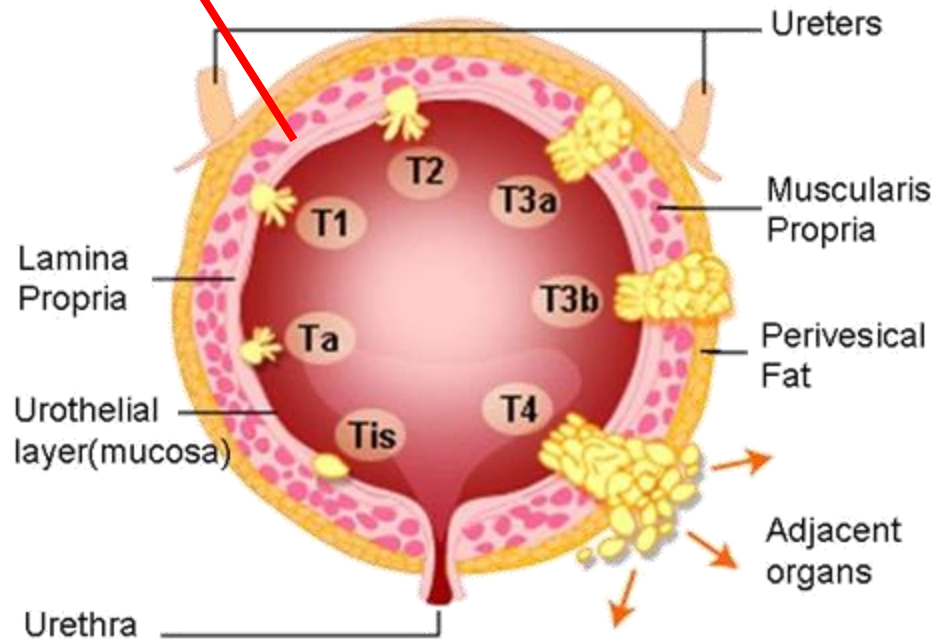


An interesting case:
(A diagnostic application of photomedicine)

The detection of early bladder cancer by fluorescence cystoscopy with Hexvix®
First studies: early 90's
First approval: 1999

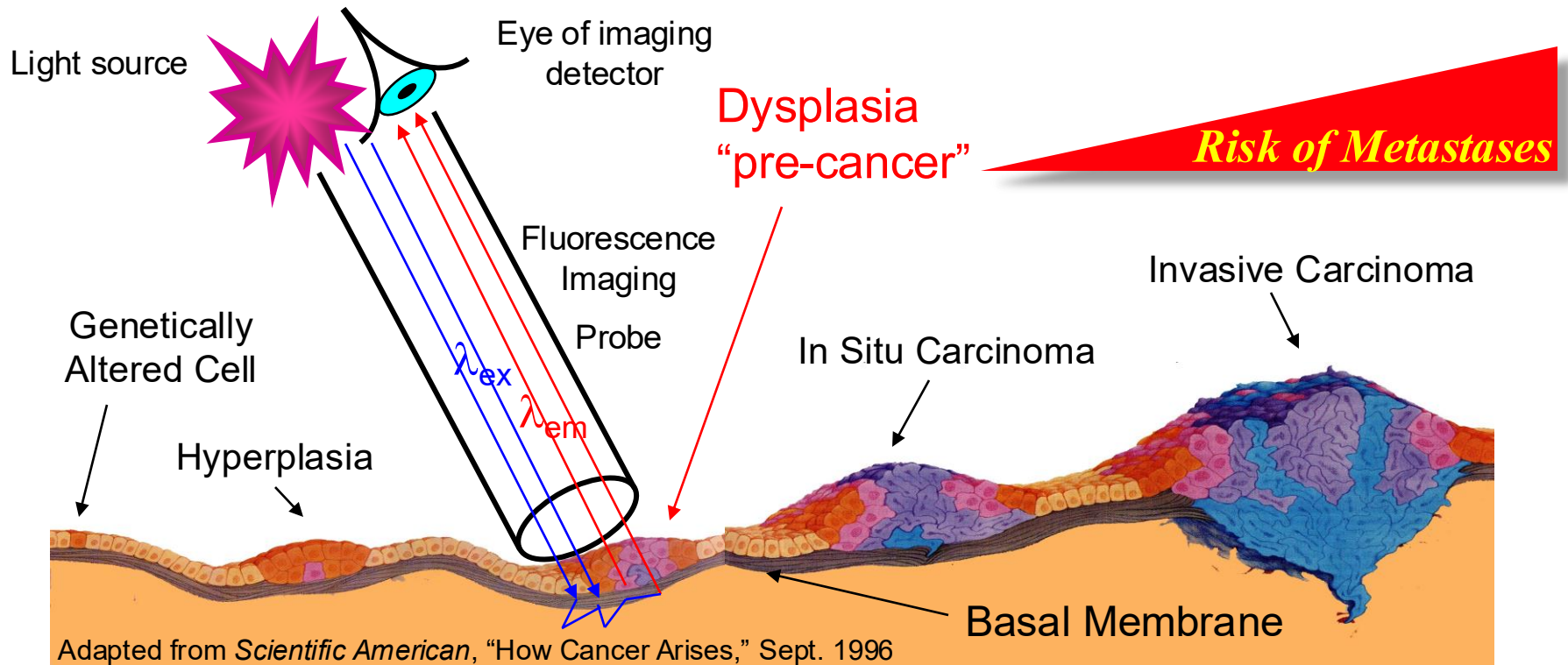


BLADDER CANCER STAGING (TNM)



Tis, Ta, T1: superficial, non-invasive
T2, T3, T4: invasive

Localization of early carcinoma by fluorescence imaging: Principle

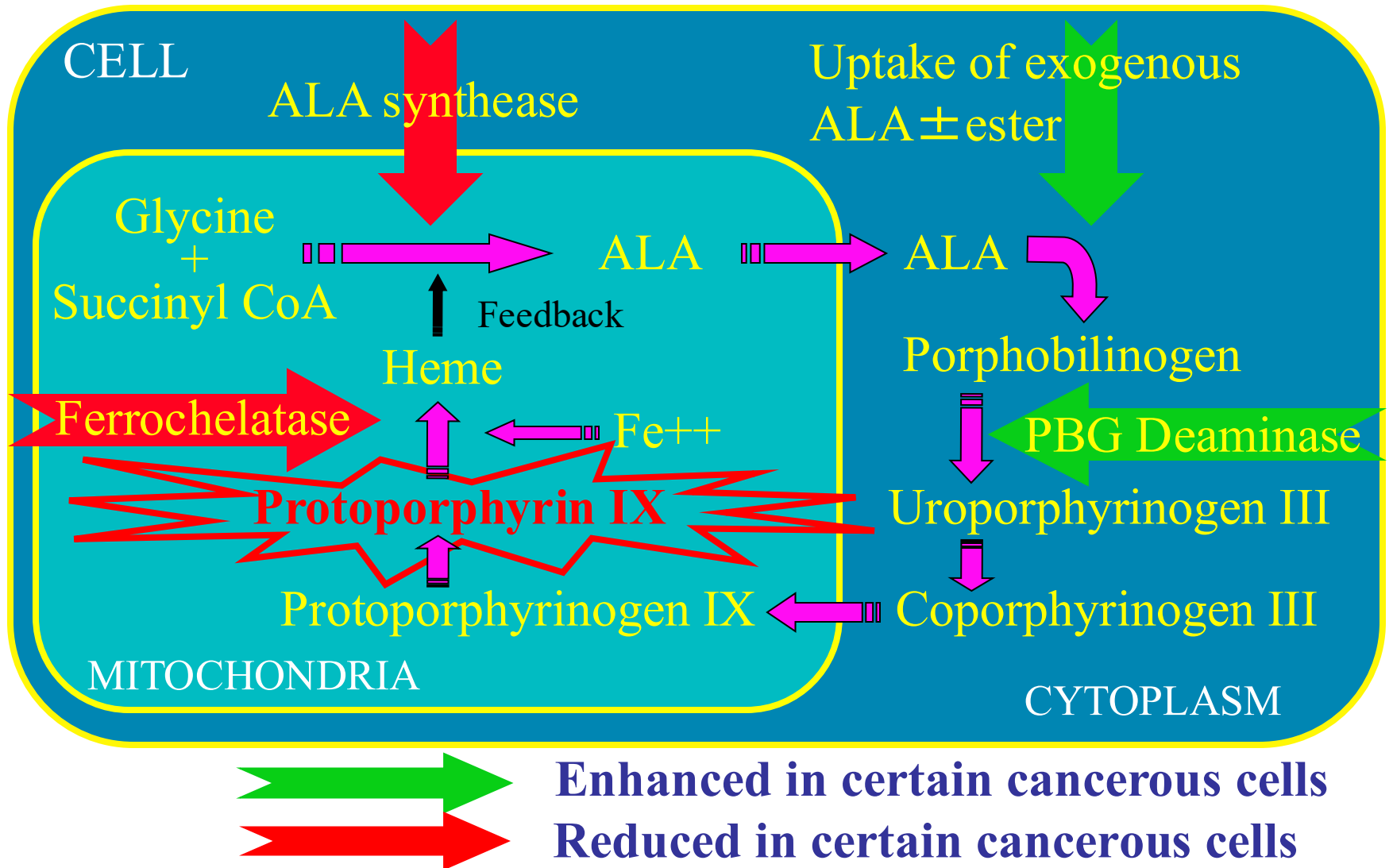


Stages detectable by conventional methods

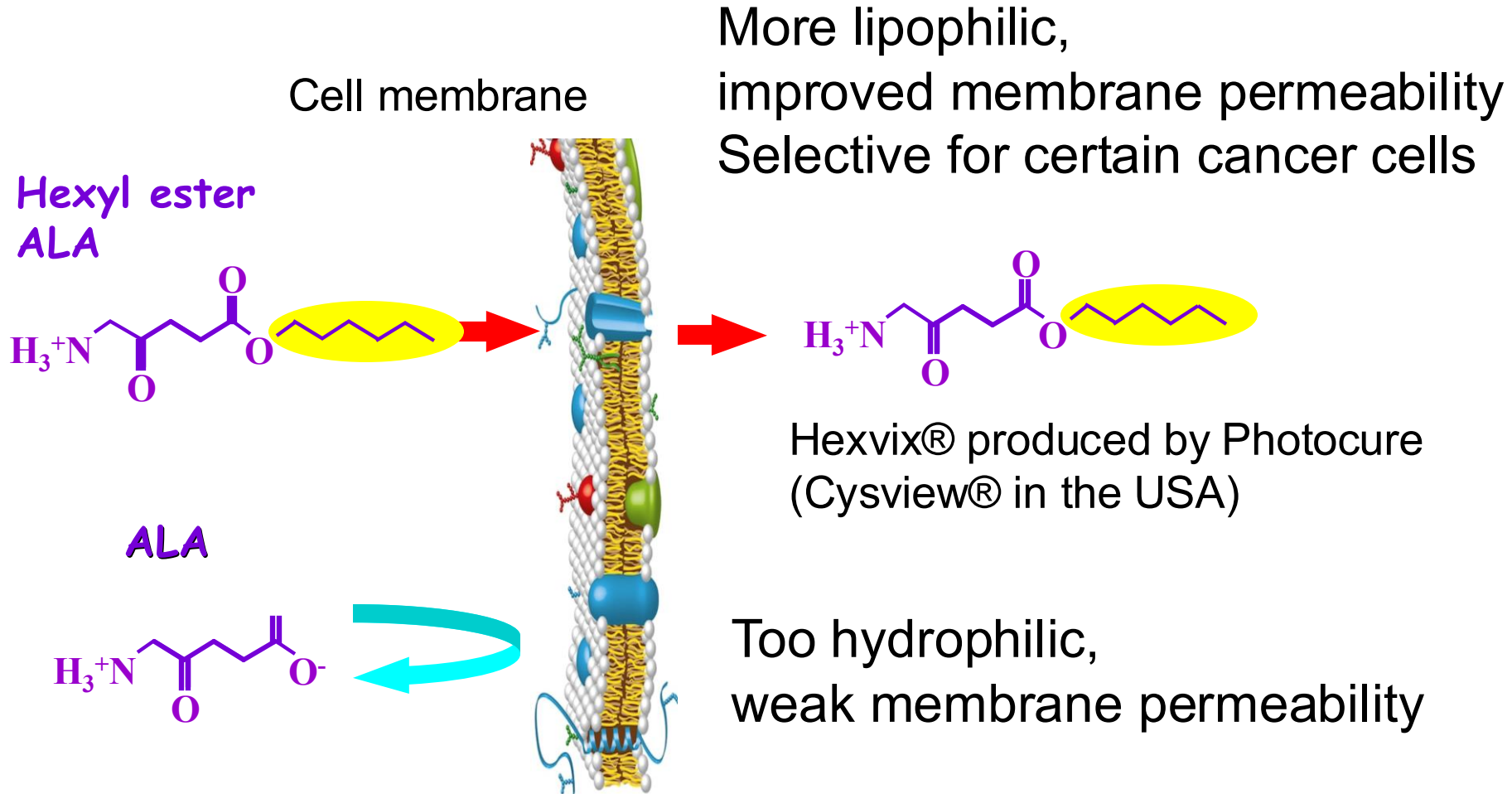
Fluorescence imaging



Aminolevulinic acid (ALA)-induced production of protoporphyrin IX in the biosynthetic pathway of heme



Advantage of Esters of Aminolevulinic Acid



Lange et al., BJC, 1999

Uehlinger et al., JP&P, 2000

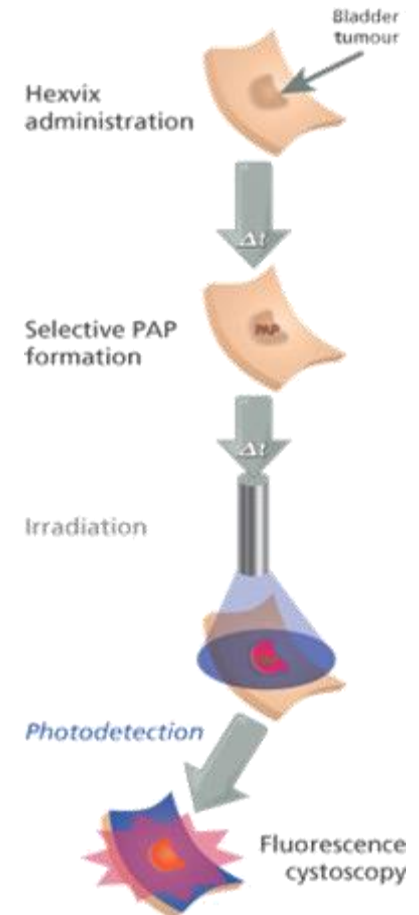
Uehlinger et al., P&P, 2006

Fluorescence cystoscopy using Hexvix®

Principes:

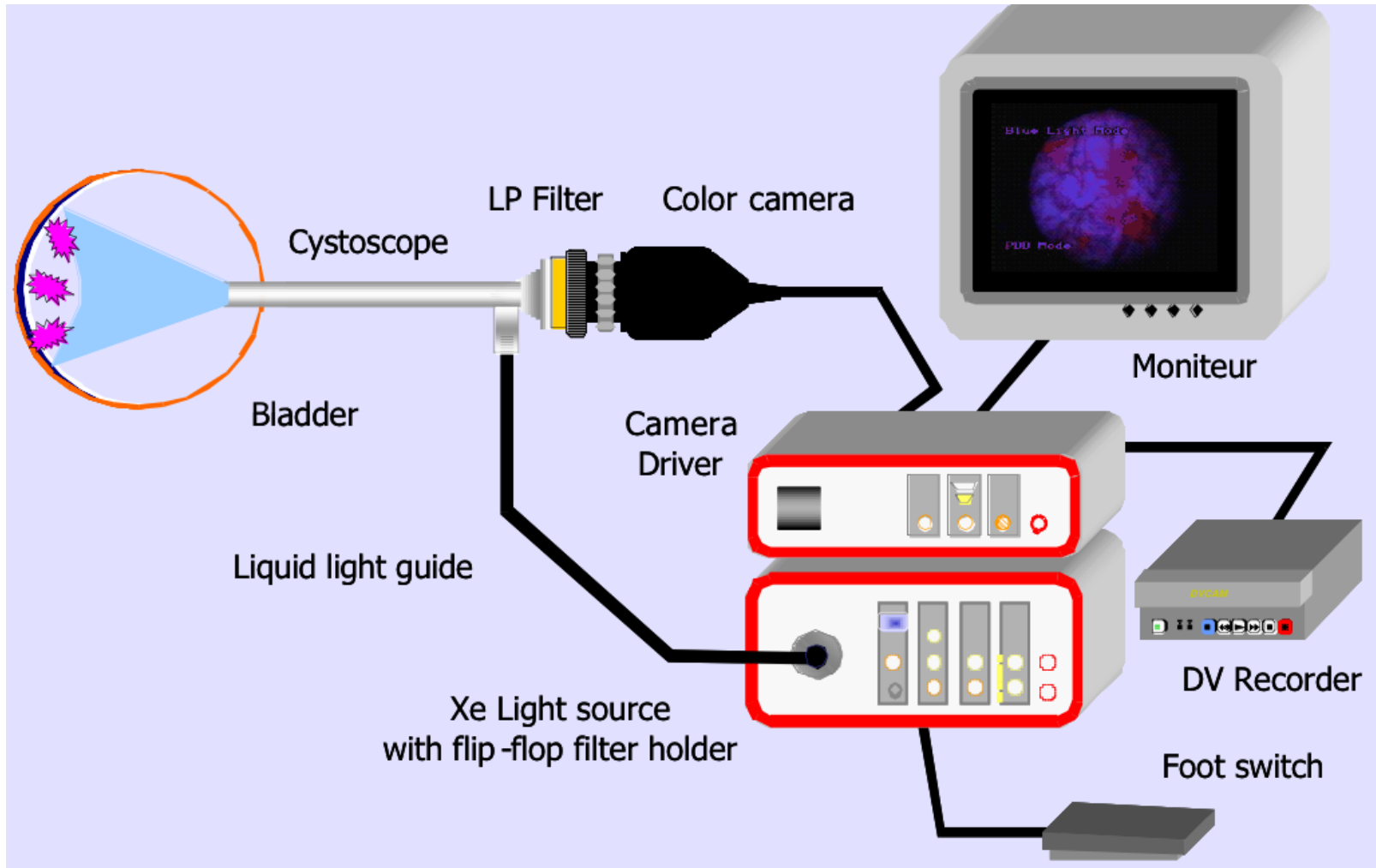
- **Instillation** (50 ml; 8 mM) of an exogenous precursor (hexylester of aminolevulinic acid, Hexvix®) of protoporphyrin IX (PpIX) during one hour prior to examination
- **Detection** of the red (peak @ 635 nm) fluorescence produced by the lesions under violet (410 nm) light excitation.

Ideal for the detection of non muscle-invasive bladder cancers !

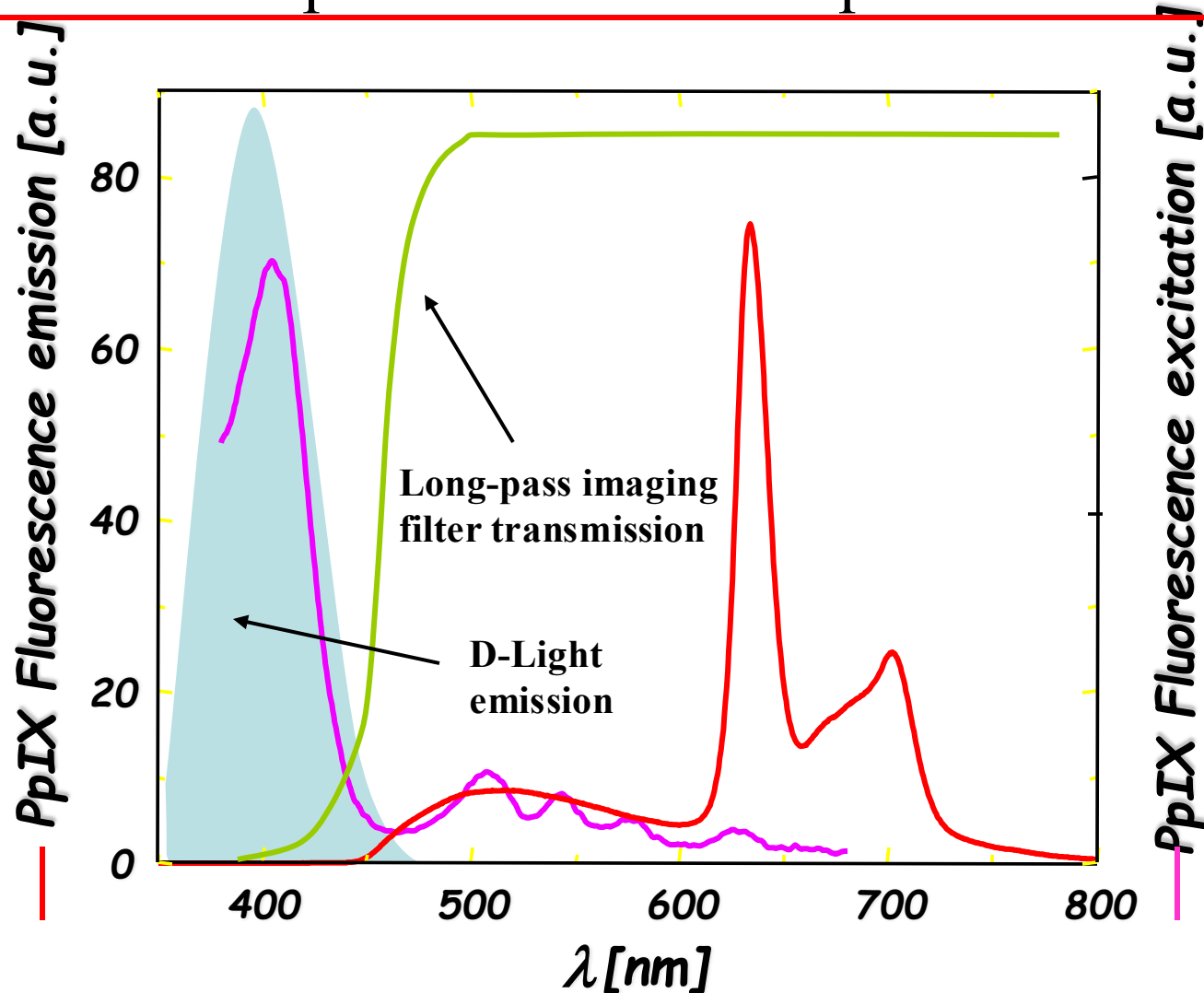


© Photocure ASA

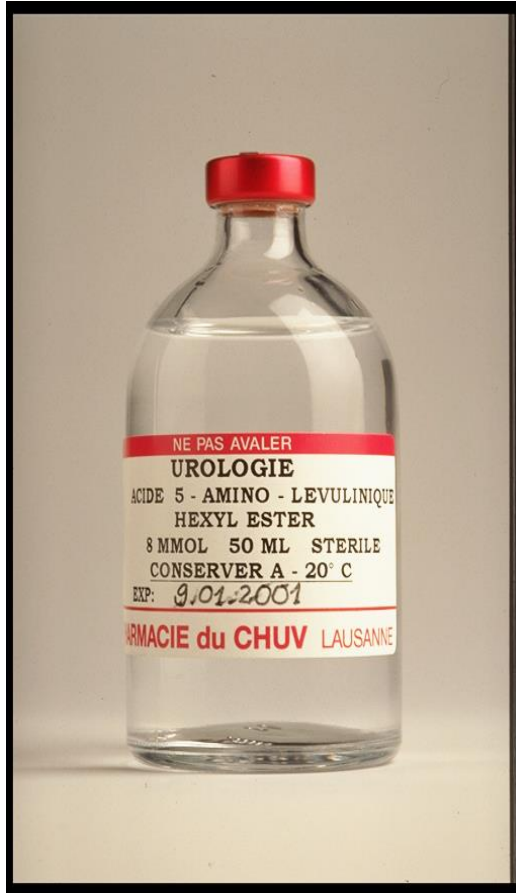

Fluorescence imaging photodetection instrumental setup



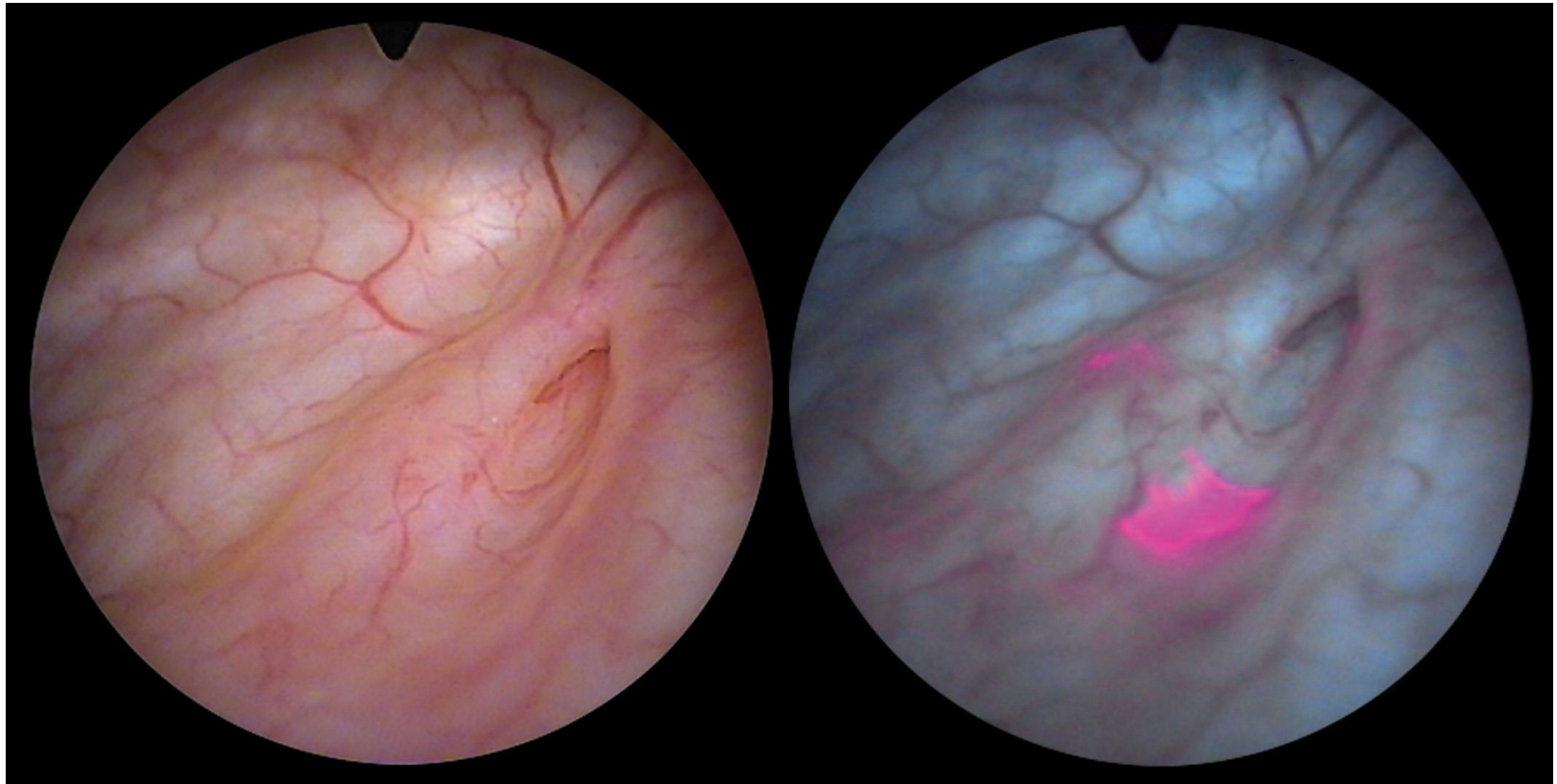
Spectral design of the fluorescence imaging photodetection setup



Combined development of Medtech and Pharma technologies



Photodetection of flat lesions (Carcinoma in situ) in the bladder



White light
Cystoscopy

ALA-Hexylester
Cystoscopy

Hexvix® Fluorescence vs White Light Cystoscopy: Key Clinical Benefits

- **Very good sensitivity** (93%) vs. WL (73%)

Indeed, fluorescence cystoscopy (FC) detects :

At least one more CIS detected in 41.5% of the patients.

Fradet et al., J. Urol 2007

One more pTa or pT1 in ~30% of the patients

Grossman et al., J. Urol 2007

- **Limited specificity** (61%) vs. WL (65%)

mainly due to high rate of false positive :

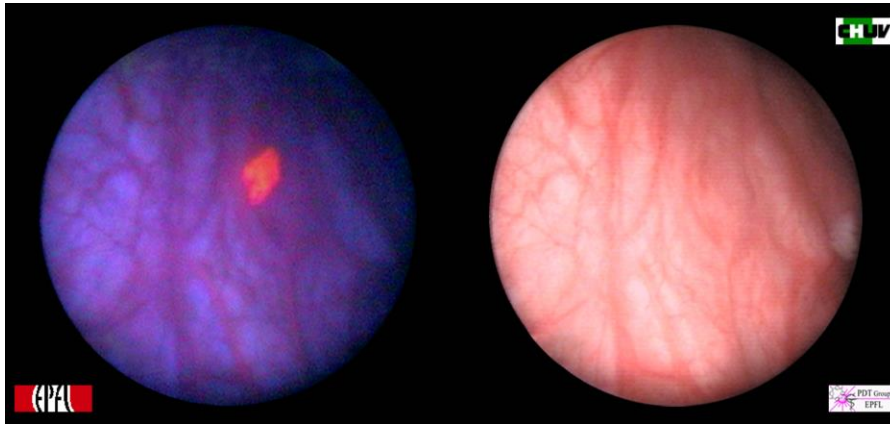
inflammation, hyperplasia, metaplasia are often cause of false-positive intravesical therapy (BCG), geometrical aspects.

Draga et al. Eur Urol 2009; Jichlinski et al. J.Urol 2003;

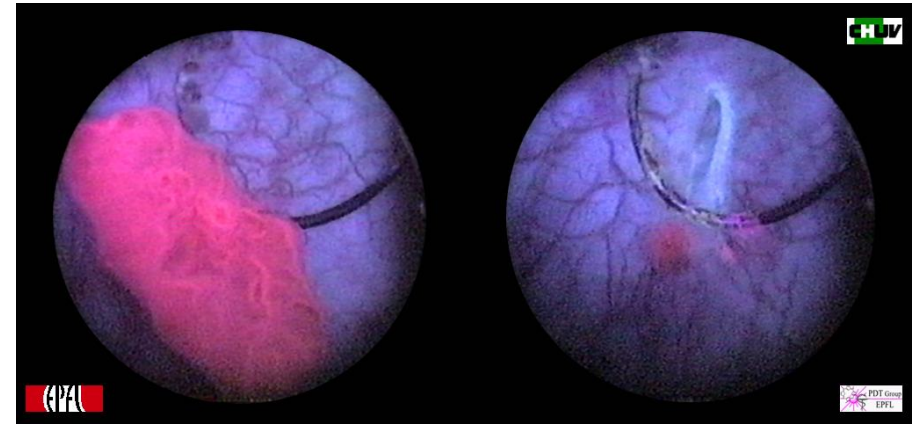
Lerner et al., Urologic Oncology 2011.

Cancer detection by endoscopic fluorescence imaging with a contrast agent (bladder cancer)

2003 Hexvix® (hexyl-ester ALA) topically



Fluorescence detection of small CIS



Fluorescence guided resection

Hexvix® and Cysview® are now commercialized by Photocure and Ipsen

Between 50'000 and 100'000 procedures / year at present

- **Approved** in all EU/EEA countries in 2005.
- **Recommended** in 2005 as standard method by the European Association of Urology
- **Reimbursement** obtained in many European countries since 2007
- **Approval** of Cysview® by the US FDA in May 2010
- **Approval** of the fluorescence cystoscopy system from Karl Storz by the US FDA in May 2012
- **Approval** of the extension of Cysview® to include Flexible Cystoscopes, which are used in the ongoing surveillance of patients with bladder cancer in 2018

